

The Role of Performing Lateral partial Internal Sphincterotomy in Patients Who Undergo Excisional Hemorrhoidectomy

Dr. Ayman Nadeem Kadum¹, Dr. Abdalrahman Hammad Turfa Al-Ani², and Dr. Husham Fadhil Hussein Al-Asadi³

¹(M.B.Ch.B, F.I.C.M.S) General Surgeon, Department of Surgery, Al-Yarmouk Teaching Hospital, Baghdad, Iraq

²(M.B.Ch.B, C.A.B.S) General Surgeon, Department of Surgery, Al-Yarmouk Teaching Hospital, Baghdad, Iraq

³(M.B.Ch.B, F.I.C.M.S, D.G.S) General Surgeon, Department of Surgery, Al-Yarmouk Teaching Hospital, Baghdad, Iraq

Abstract: Background: Excisional hemorrhoidectomy is a commonly performed surgical procedure for treating hemorrhoids, however, postoperative pain is a significant concern. Lateral partial internal sphincterotomy (LIS) is a surgical technique that aims to alleviate postoperative pain by partially dividing the internal anal sphincter muscle. **Objectives:** This study aims to evaluate the effect of lateral internal sphincterotomy on postoperative pain and complications in those undergoing excisional hemorrhoidectomy. **Patients and Method:** This non-randomized controlled study was conducted from February 2020 to April 2022 at Al-Yarmouk Teaching Hospital. One hundred patients who underwent excisional haemorrhoidectomy were included in this research. Fifty patients with Hypertension and Fifty patients without hypertension. Fifty patients had an additional lateral internal sphincterotomy (LIS) procedure comprising the study arm, and Fifty patients did not have such procedure (control arm). Demographic data and data about postoperative pain and complications were recorded. **Results:** The mean age of the participants was 40.6 ± 10.7 years for the control arm and 35.9 ± 7.7 years for the study arm. Males constituted 66 and 76% of the total in the control and study groups, respectively. Postoperative pain in the first six hours and three days after surgery as well as following bowel movement was significantly less among patients undergoing LIS. However, no significant difference was noticed in pain severity in the first and second postoperative weeks. Bleeding was significantly of lower occurrence in the study group, while urine retention did not show any significant difference in frequency among both groups. **Conclusion:** Lateral internal sphincterotomy significantly reduces pain severity, especially in the early postoperative period with a decreased hospital stay. It also decreases some complications related to excisional hemorrhoidectomy such as bleeding.

Keywords: Lateral, Internal, Sphincterotomy, Excisional, Hemorrhoidectomy.

INTRODUCTION

Hemorrhoids, known as piles, a condition characterized by the downward displacement of dilated submucosal vascular anal cushions, commonly located at 3, 7, and 11 o'clock in the anal canal. It is a common condition which presents with complaints of bleeding per rectum, pain at rest and defecation, mucosal discharge, and prolapse [Taha, S.A, 2013]. Hemorrhoids can be classified into two categories: internal and external, depending on their position in relation to the pectinate line. Internal hemorrhoids are found inside the rectum, while external hemorrhoids are located within the anus and may protrude externally, typically occurring during bowel movements [Warwick, R. *et al.*, 2008]. Internal hemorrhoids are classified based on the severity or degree of the hemorrhoids [Sun, Z. *et al.*, 2016]. It is commonly believed that constipation and persistent straining can lead to the development of hemorrhoids. This is because the passage of hard stool and the raised pressure within the abdomen can obstruct normal venous blood flow, causing the blood vessels in the hemorrhoidal plexus to become swollen and engorged [Loder, P.B. *et al.*, 1994]. In the United States, approximately 10 million individuals reported experiencing hemorrhoids, resulting in a prevalence rate of 4.4%. Among both males and females, the highest occurrence of hemorrhoids was observed between

the ages of 45 and 65 years [Johanson, J.F. *et al.*, 1990]. An online survey involving populations from multiple countries identified a prevalence of 11% among participants who self-reported having hemorrhoidal disease [Sheikh, P. *et al.*, 2020]. For third, and fourth-degree hemorrhoids, the most effective treatment option is hemorrhoidectomy. However, one significant drawback of this surgical procedure is the presence of postoperative pain during the first week. This pain primarily occurs due to the contraction of the internal sphincter, particularly in younger patients who tend to have a higher anal tone [Liu, J.W. *et al.*, 2016]. Lateral internal sphincterotomy (LIS) is a surgical technique that involves the partial division of the internal anal sphincter muscle. It has been proposed as an adjunct procedure to excisional hemorrhoidectomy to alleviate postoperative pain by reducing anal sphincter spasm and tension. While several studies have investigated the use of LIS in combination with hemorrhoidectomy, the evidence regarding its effectiveness remains inconclusive [Vijayaraghavalu, S. *et al.*, 2021]. A literature review by Emile, *et al.*, [2016] showed nearly all studies examining postoperative pain have consistently shown that patients who underwent lateral internal sphincterotomy experienced lower pain scores and required less postoperative pain medication compared to those

who did not undergo LIS. In a similar fashion, a study by Galizia, *et al.*, [2000] revealed that pain as well as connected complications were observed to be improved after applying LIS to excisional hemorrhoidectomy. On the other hand, no significant role for LIS in reducing post-hemorrhoidectomy pain was found by Khubchandani, *et al.*, [2002]. This study aims to further evaluate the effect of lateral partial internal sphincterotomy on postoperative pain and complications in those undergoing excisional hemorrhoidectomy.

PATIENTS AND METHOD

Study Design and Settings

This non-randomized controlled study was conducted from February 2020 to April 2022 at Al-Yarmouk Teaching Hospital.

Data Collection

One hundred patients who had excisional hemorrhoidectomy during the period of the study were included in this research. Fifty patients had an additional lateral internal sphincterotomy (LIS) procedure and fifty patients did not have such procedure. Data collection included demographic information as well as postoperative pain severity at different times following the operation (6 hours, 3, 7, and 14 days) in addition to pain after bowel motion. Postoperative complications including bleeding and urine retention, and time taken to return to work were recorded.

Study Groups

Two arms were defined in this study:

- Study arm: 50 cases underwent LIS in addition to excisional hemorrhoidectomy.
- Control arm: 50 cases underwent excisional hemorrhoidectomy only.

Outcome Assessment

Pain severity was assessed using the Visual Analog Scale (VAS) scoring ranging from 0 to 10 points, where 0 indicates no pain and 10 the worst pain; pain severity was then categorized into mild (1-3 points), moderate (4-7 points) and severe (8-10 points) [Delgado, D.A. *et al.*, 2018]. Time taken to return to work was recorded as the number of postoperative days elapsed before resuming work.

Inclusion Criteria

All patients who underwent excisional hemorrhoidectomy for symptomatic hemorrhoids were included in the study.

Exclusion Criteria

Patients with age above 60 years old were excluded, as well as patients with recurrent haemorrhoids or previous anal surgery also excluded and patients who were found to have any concomitant perianal pathology such as perianal fissure, perianal fistula, rectal prolapse, incontinence or abscesses were excluded too.

Statistical Analysis

Continuous variables were expressed as means and standard deviations. Categorical variables were expressed as frequency and percentages. The Welch's t-test (for normally distributed variables) was performed. The difference between categorical variables was investigated using either the χ^2 test with Yates' correction or Fisher's exact test, depending on the context.

P-value less than 0.05 was considered statistically significant. R software packages (dplyr, gt_summery, and ggplot) were used for data processing, visualization, and statistical analysis ("R version 4.2.2, R Foundation for Statistical Computing, Vienna, Austria").

Ethical issues

Ethical and scientific approval for the research was obtained from the Scientific Committee at the Department of [Subject], Al-Yarmouk Teaching Hospital. Verbal consent was obtained from all patients before starting data collection and after explaining the aims of the study and assuring confidentiality.

RESULTS

Patient's Demographics

A total of 100 participants were included in the study. 50 participants were allocated to the study arm and the other 50 to the control arm. The mean age was (40.6 ± 10.7 years) in the control group and (35.9 ± 7.7 years) in the study group with statistically significant difference among both groups (P-value = 0.014). Most of the participants were males in both groups, with no statistical difference regarding the sex.

Table 1: Description of Patient's demographics.

Characteristic	Control arm, N = 50 ¹	Study arm, N = 50 ¹	P-value ²
Age, years	40.6 ± 10.7	35.9 ± 7.7	0.014
Sex			0.3
<i>Male</i>	33 (66.0%)	38 (76.0%)	
<i>Female</i>	17 (34.0%)	12 (24.0%)	
¹ Mean ± SD; n (%)			
² Welch Two Sample t-test; Pearson's Chi-squared test			

Severity of Postoperative Pain

The vast majority of patients in the study group (98%) reported mild pain 6 hours following the operation, whereas most patients in the control group (70%) rated their pain as moderate. On the other hand, moderate pain was reported by the study group in most patients (94%) three days post-operatively. At both of the aforementioned post-operative timings (i.e., after 6 hours and 3 days) a statistically significant difference in pain severity was noticed between the control and study

groups (P-value < 0.001). Seven and fourteen days after the operation, both groups reported mild pain by most participants with no statistical difference between them. Regarding pain after bowel motion, most patients mentioned moderate pain in both groups, while severe pain was reported by a significantly smaller number of the study arm compared to the control arm (8% vs. 28%, respectively; P-value = 0.017).

Table 2: Severity of postoperative pain in both the study group and the control group.

Post-operative pain	Control arm, N = 50 ¹	Study arm, N = 50 ¹	P-value ²
After Six hours			<0.001
<i>Mild</i>	0 (0.0%)	49 (98.0%)	
<i>Moderate</i>	35 (70.0%)	1 (2.0%)	
<i>Severe</i>	15 (30.0%)	0 (0.0%)	
After 3 days			<0.001
<i>Mild</i>	17 (34.0%)	3 (6.0%)	
<i>Moderate</i>	27 (54.0%)	47 (94.0%)	
<i>Severe</i>	6 (12.0%)	0 (0.0%)	
After 7 days			0.5
<i>Mild</i>	43 (86.0%)	45 (90.0%)	
<i>Moderate</i>	7 (14.0%)	5 (10.0%)	
After 14 days			>0.9
<i>Mild</i>	49 (98.0%)	49 (98.0%)	
<i>Moderate</i>	1 (2.0%)	1 (2.0%)	
Pain after bowel motion			0.017
<i>Mild</i>	0 (0.0%)	1 (2.0%)	
<i>Moderate</i>	36 (72.0%)	45 (90.0%)	
<i>Severe</i>	14 (28.0%)	4 (8.0%)	
¹ n (%)			
² Pearson's Chi-squared test; Fisher's exact test			

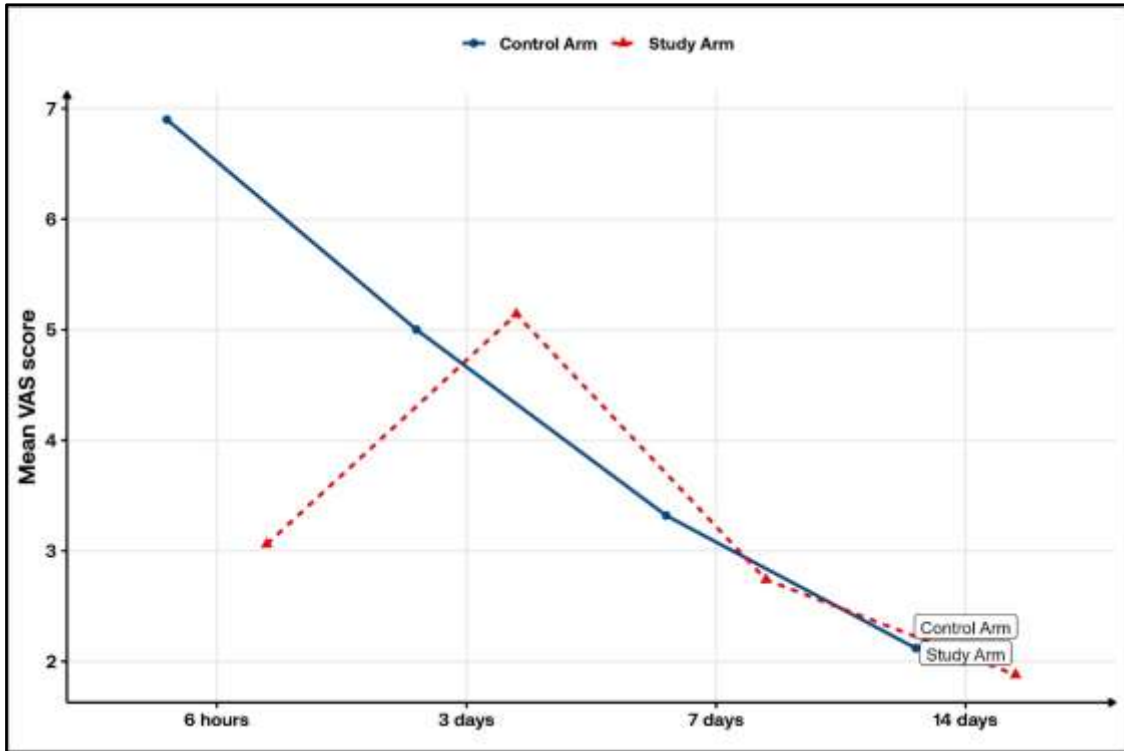


Figure 1: The mean VAS score regarding pain after bowel motion in both study groups

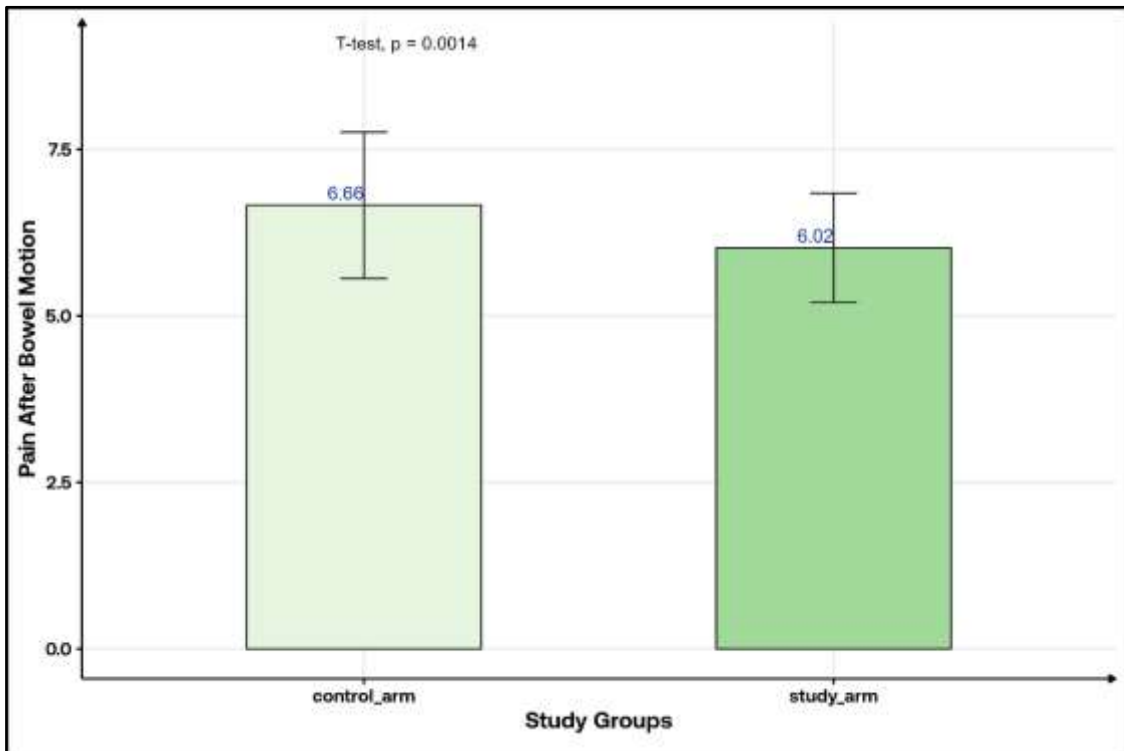


Figure 2: The mean VAS score regarding pain after bowel motion in both study groups

Incidence of postoperative complications and description of the time taken to return to work
 Concerning the postoperative complications, bleeding was observed mainly among participants of the control group (28%), while only 4% of the study arm participants suffered the aforementioned complication (P-value = 0.001). Similarly, urine

retention was reported in 10% of the control group patients. On the other hand, none of the study group participants had such complication. The time taken to return to work was significantly shorter among those in the study arm as opposed to subjects in the control arm (10.4 ± 1.9 days and 20.3 ± 5.2 days, respectively; P-value < 0.001).

Table 3: Incidence of post-operative complications, and description of the time it took to return to work.

Parameter	Control arm, N = 50 ¹	Study arm, N = 50 ¹	P-value ²
Post-operative complication			
<i>Bleeding</i>	14 (28.0%)	2 (4.0%)	0.001
<i>Urine retention</i>	5 (10.0%)	0 (0.0%)	0.056
Return to work (days)	20.3 ± 5.2	10.4 ± 1.9	< 0.001
¹ Mean ± SD; n (%)			
² Welch Two Sample t-test; Fisher's exact text			

DISCUSSION

Excisional hemorrhoidectomy is a widely accepted surgical method used to address severe or symptomatic hemorrhoids. Nevertheless, the occurrence of postoperative pain poses a significant concern, affecting patient recovery and satisfaction. To mitigate this issue, lateral internal sphincterotomy (LIS) has been introduced as an additional surgical technique, involving partial division of the internal anal sphincter muscle. The primary aim of LIS in conjunction with excisional hemorrhoidectomy is to alleviate postoperative pain by reducing anal sphincter spasm and tension. Despite various studies investigating this combined approach, the available evidence regarding the effectiveness of LIS remains inconclusive [Vijayaraghavalu, S. *et al.*, 2021]. The primary objective of the current study is to assess the impact of LIS on postoperative outcomes, including pain levels. Additionally, potential complications of the procedure will be investigated. The mean age of participants in the control and study group was 35.9 ± 7.7 and 40.6 ± 10.7 years, respectively; with the study arm participants being significantly older than their control arm counterparts (P-value = 0.014). In contrast, other studies [Kanellos, I. *et al.*, 2005; 14.

Arija, D. *et al.*, 2022] showed no significant difference in age between the two groups. Male patients comprised up to two-thirds of each group with no statistical difference between the two groups. This is in accordance with what Arija, *et al.*, [2022] had. The current study showed that postoperative pain was significantly milder among those patients undergoing LIS in addition to excisional hemorrhoidectomy, which was particularly true in the early post-surgical period. Mild pain was reported by up to 98% of the study arm participants about 6 hours after the operation, while around two-thirds of the control group (70%) reported having a moderate pain severity at that time; additionally, 30% of them had severe pain requiring more potent analgesia. A similar trend was noticed on the third post-

operative day, where the vast majority (94%) of those having an additional LIS mentioned experiencing moderate pain with no reported cases of severe pain; on the other hand, up to 12% of the patients who did not have an LIS procedure described a severe pain. The one- and two-week postoperative pain, on the other hand, showed no significant difference in terms of severity between both groups. Similar to our results, Vijayaraghavalu, *et al.*, [2021] and Arija, *et al.*, [2022] reported significantly less severe pain in the early postoperative period among those having combined hemorrhoidectomy and LIS. Moreover, Galizia, *et al.*, [2000], Kanellos *et al.*, [2005], Diana, *et al.*, [2009], and Wang, *et al.*, [2018] reported improved postoperative pain in the study group in both early and late post-surgical periods. On the other hand, Khubchandani, *et al.*, [2002] and Hosseini, *et al.*, [2007] did not find any significant difference concerning pain severity between those who underwent LIS and those who did not. However, this was attributed to performing LIS distal to the dentate line, terminating at the inter-sphincteric groove [Khubchandani, I.T, 2011]. Pain following bowel motion was found to be significantly less severe in the study compared to the control group as more than one-quarter (28%) of the control group reported having severe pain after their first postoperative bowel movement, whereas such pain was reported by none of the study group participants. Kanellos, *et al.*, [2005] had similar results. Khubchandani, *et al.*, [2002] on the other hand, showed no significant difference in pain severity between the two groups. Regarding postoperative complications, bleeding was experienced by about (4%) of the study arm participants which is significantly less than that observed among the patients in the study arm (28%) (P-value = 0.001). This is similar to what Vijayaraghavalu, *et al.*, [2021] and Arija, *et al.*, [2022] had. Nevertheless, Wang, *et al.*, [2018] reported a non-significant impact of having LIS on the incidence of post-hemorrhoidectomy bleeding.

At the same time, they considered their result an additional point towards performing LIS in patients undergoing excisional hemorrhoidectomy, proving LIS as a safe procedure in those patients. After undergoing hemorrhoidectomy, it is not uncommon for patients to experience urinary retention, which occurs in approximately 15.2% of cases. This condition is often attributed to dysfunction in the detrusor muscle in response to pain signals, or due to the distension of the anal canal or perineum [Chik, B. *et al.*, 2006]. This study did not show significant benefits for performing an LIS procedure concerning the occurrence of urine retention as a complication of excisional hemorrhoidectomy. This finding was in concordance with what Galizia, *et al.*, [2000], Wang, *et al.*, [2018], and Hosseini, *et al.*, [2007] concluded. Emile, *et al.*, [2016] and Vijayaraghavalu, *et al.*, [2021], on the other hand, inferred that LIS significantly reduces the incidence of post-hemorrhoidectomy urine retention, most probably secondary to reduced postoperative pain. As a result of reducing postoperative pain and complication rate, performing a LIS in combination with excisional hemorrhoidectomy, have shown to significantly shorten the postoperative hospital stay and allow early return to work (mean time to return to work of 10.4 ± 1.9 days and 20.3 ± 5.2 days, for the study group and control group, respectively), which is identical to what Wang, *et al.*, [2018] inferred. It is worth mentioning that this study has some limitations including a small sample size which could limit the generalizability of the results as well as its retrospective design.

In conclusion, the addition of LIS to excisional hemorrhoidectomy has been shown to significantly reduce pain severity, especially in the early postoperative period, which could promote an early return to daily activities and work. This procedure also decreases some complications related to excisional hemorrhoidectomy such as bleeding.

REFERENCES

1. Taha, S.A. "Routine internal sphincterotomy with hemorrhoidectomy for third and fourth degree hemorrhoids greatly improves the outcome." *Iraq J Gastroenterol.* 4 (2003): 48-51.
2. Warwick, R. and Williams, P.L. "Gray's Anatomy." 36th ed. *Edinburgh: Churchill Livingstone* 8 (2008).
3. Sun, Z. and Migaly, J. "Review of Hemorrhoid Disease: Presentation and Management." *Clin Colon Rectal Surg* 29 (2016):22.
4. Loder, P.B., Kamm, M.A., Nicholls, R.J. and Phillips, R.K.S . "Haemorrhoids: pathology, pathophysiology and aetiology." *British journal of surgery* 81.7 (1994): 946-954.
5. Johanson, J.F. and Sonnenberg, A . "The prevalence of hemorrhoids and chronic constipation: an epidemiologic study." *Gastroenterology* 98.2 (1990): 380-386.
6. Sheikh, P., Régnier, C., Goron, F. and Salmat, G . "The prevalence, characteristics and treatment of hemorrhoidal disease: results of an international web-based survey." *Journal of comparative effectiveness research* 9.17 (2020): 1219-1232.
7. Liu, J.W., Lin, C.C., Kiu, K.T., Wang, C.Y. and Tam, K.W . "Effect of glyceryl trinitrate ointment on pain control after hemorrhoidectomy: a meta-analysis of randomized controlled trials." *World journal of surgery* 40 (2016): 215-224.
8. Vijayaraghavalu, S., Rajkumar, S. and Prasad, G. "The role of lateral internal sphincterotomy in haemorrhoidectomy: a study in a tertiary care center." *Cureus* 13.6 (2021).
9. Emile, S.H., Youssef, M., Elfeki, H., Thabet, W., El-Hamed, T.M.A. and Farid, M. "Literature review of the role of lateral internal sphincterotomy (LIS) when combined with excisional hemorrhoidectomy." *International journal of colorectal disease* 31 (2016): 1261-1272.
10. Galizia, G., Lieto, E., Imperatore, V., Pelosio, L. and Castellano, P. "The usefulness of lateral internal sphincterotomy combined with hemorrhoidectomy in the treatment of hemorrhoids: a randomized prospective study." *Il Giornale di chirurgia* 21.3 (2000): 127-134.
11. Khubchandani, I.T. "Internal sphincterotomy with hemorrhoidectomy does not relieve pain: a prospective, randomized study." *Dis Colon Rectum* 45 (2002):1452-7.
12. Delgado, D.A., Lambert, B.S., Boutris, N., McCulloch, P.C., Robbins, A.B., Moreno, M.R. and Harris, J.D . "Validation of digital visual analog scale pain scoring with a traditional paper-based visual analog scale in adults." *Journal of the American Academy of Orthopaedic Surgeons. Global research & reviews* 2.3 (2018).
13. Kanellos, I., Zacharakis, E., Christoforidis, E., Angelopoulos, S., Kanellos, D., Pramateftakis,

- M.G. and Betsis, D. "Usefulness of lateral internal sphincterotomy in reducing postoperative pain after open hemorrhoidectomy." *World journal of surgery* 29 (2005): 464-468.
14. Arija, D., Melwani, R., Jabeen, S., Kumar, R., Sial, I. and Tasneem, B., *et al.* "Outcomes after Hemorrhoidectomy with or Without Lateral Sphincterotomy: An Observational Study." *J Res Med Dent Sci* (2022): 10.
15. Diana, G., Guercio, G., Cudia, B. and Ricotta, C. "Internal sphincterotomy reduces postoperative pain after Milligan Morgan haemorrhoidectomy." *BMC surgery* 9 (2009): 1-6.
16. Wang, W.G., Lu, W.Z., Yang, C.M., Yu, K.Q. and He, H.B. "Effect of lateral internal sphincterotomy in patients undergoing excisional hemorrhoidectomy." *Medicine* 97.32 (2018).
17. Hosseini, S.V., Sharifi, K., Ahmadfard, A., Mosallaei, M., Pourahmad, S. and Bolandparvaz, S. "Role of internal sphincterotomy in the treatment of hemorrhoids: a randomized clinical trial." *Arch Iran Med* 10 (2007):504–8.
18. Chik, B., Law, W.L. and Choi, H.K. "Urinary retention after haemorrhoidectomy: Impact of stapled haemorrhoidectomy." *Asian Journal of Surgery* 29.4 (2006): 233-237.

Source of support: Nil; **Conflict of interest:** Nil.

Cite this article as:

Kadum, A.N., Al-Ani, A.H.T. and Al-Asadi, H.F.H. "The Role of Performing Lateral partial Internal Sphincterotomy in Patients Who Undergo Excisional Hemorrhoidectomy." *Sarcouncil Journal of Medicine and Surgery* 2.7 (2023): pp 13-19.