

## Uniportal Biportal Endoscopic Lumbar Discectomy (UBELD) versus Open Microdiscectomy: A Randomized Controlled Trial on Pain Relief and Functional Recovery

Dr. Wisam Hussein Mohammed<sup>1</sup>, Dr. Ayad Yaseen Mutar<sup>2</sup> and Dr. Aiham Mahdi Hammad<sup>3</sup>

<sup>1</sup>M.B.Ch.B., F.I.C.M.S. (Neurosurgery), Iraqi Ministry of Health, Al-Anbar Health Directorate, Al-Ramadi Teaching Hospital, Al-Anbar, Iraq.

<sup>2</sup>M.B.Ch.B., C.A.B.M.S. (Orthopedic Surgery), Iraqi Ministry of Health, Al-Anbar Health Directorate, Al-Ramadi Teaching Hospital, Al-Anbar, Iraq.

<sup>3</sup>M. B. Ch. B, Facharzt, Germany (Orthopedic Surgery). 2020 S. U. C. (Trauma Surgery). Germany 2022 D. A. F. (Foot Surgery). Germany 2023, S. U. C. (Hand surgery). 2025, Iraqi Ministry of Health, Iraq.

**Abstract:** Open microdiscectomy (OM) has remained the surgical gold standard; however, minimally invasive endoscopy has become available to potentially minimize tissue trauma and hasten recovery. A new approach, which is just coming into the picture, is called “Miniaturized Endoscopic Lumbar Discectomy” or “Uniportal Biportal Endoscopic Lumbar Discectomy” (UBELD). The purpose of this paper is to compare and assess the efficacy, safety, and recovery outcomes of UBELD and conventional OM in patients undergoing surgery for a herniated disc in the lumbar spine, the primary outcomes being for pain relief and functional recovery. In addition, a prospective randomized controlled trial was performed with 121 patients with symptomatic lumbar disc herniation who were randomly assigned to UBELD (n=60) or OM (n=61). There were no significant differences between groups in baseline demographics. Primary outcomes were Visual Analog Scale (VAS) scores of back and leg pain and Oswestry Disability Index (ODI) scores. Secondary outcomes included operative time, EBL, hospital stay, complications, recurrence at 12 months, time to return to daily activities, patient satisfaction, and postoperative analgesic consumption. An assessment was conducted preoperatively, and then at 24 hours, 6 weeks, 6 months, and 12 months postoperatively. Additionally, there was a clear clinical improvement in both groups. UBELD was associated with longer operative time (58.4±12.2 vs. 46.2±9.8 min) but significantly reduced estimated blood loss (15.5±5.2 vs. 42.8±12.4 mL), shorter hospital stay (22.4±4.5 vs. 44.8±10.2 hours), and markedly lower analgesic consumption at 24 hours (15.2±5.5 vs. 35.8±8.2 MME). At 24 hours, pain was better with UBELD both for back pain (VAS: 2.8±0.8 vs. 4.2±1.04) and for leg pain (2.1±0.7 vs. 3.5±0.9) and remained better at 6 weeks. At 6 weeks, functional recovery (ODI) was improved in UBELD (18.2±4.5 vs. 20.1±4.9); these differences between groups became less pronounced at 6 months. Complication rates (5.0% vs. 8.2%) and 12-month recurrence rates (3.3% vs. 4.9%) were comparable. UBELD had a significant impact on early return to daily life, with no differences in patient satisfaction, yet high satisfaction rates in both groups (12.4±3.5 vs. 22.6±5.2 days). In conclusion, UBELD is considered as a safe and effective minimally invasive option for treating LDHs that eliminates the need for open microdiscectomy. UBELD is superior in perioperative parameters, early postoperative pain control and analgesic requirement, shortened hospital stay, and rapid return to daily activities, while long-term pain relief and functional outcome are comparable. The results confirm UBELD as a good alternative for certain patients who want to achieve a faster recovery but at the same safety level as regular LED.

**Keywords:** Uniportal Biportal Endoscopic Lumbar Discectomy (UBELD); Open Microdiscectomy; Functional Recovery; Pain Relief; and Complications.

### INTRODUCTION

Lumbar disc herniation (LDH) is one of the most common spinal conditions in adults, contributing to “low back pain” and contributing to the majority of adults that suffer from radiculopathy-related disability [Benson, R. T. *et al.*, 2010]. Usually, ongoing degeneration and extrusion of the nucleus pulposus material through a damaged annulus fibrosus leads to a mechanical and chemical irritation of the lumbosacral nerve root [Cribb, G. L. *et al.*, 2007; Lee, D. Y. *et al.*, 2009]. Despite careful nonoperative treatment plans, many LDH patients experience symptoms that are refractory to pain management or demonstrate progressive neurologic deficits or decreased quality of life after following all conservative care modalities. In clinical situations, prompt surgical decompression

is necessary to reach the goal of neurological decompression, and if necessary, it is advisable to avoid irreversible neurological catastrophe [Eum, J. H. *et al.*, 2016]. Over the past few decades, surgical approaches to the management of symptomatic LDH have evolved from the wide array of laminectomy techniques to increasingly focused, carefully targeted surgeries with a greater focus on early rehabilitation and low surgical morbidity [Soliman, H. M. *et al.*, 2013].

One of these surgical options is a long-established procedure called open microdiscectomy (OMD), which is regarded as the gold standard surgery for single-level lumbar disc herniation. Unlike the higher-powered and limited midline computational approach first developed in the late 1970s [Conrad,

J. et al., 2011], controlled resection of the ligamentum flavum and the removal of disc fragments are combined with high-powered, limited midline magnification, which can isolate only the neural structures and, with their superior precision, avoid injury to the disc and/or narrowing of the spinal canal. A variety of patient cohorts show good long-term clinical outcomes, patient satisfaction, and reproducible complications using the method [Lin, G. X. et al., 2019]. The procedure, however, in itself involves extensive dissection and retraction of paraspinal muscle, and can result in inadvertent surgery-related soft tissue trauma, denervation, and foster postoperative fibrosis [Yoon, S. M. et al., 2012].

To overcome such clinical challenges, there is a new alternative that is growing as a promising and minimally invasive alternative to clinical practices: Uniportal Biportal Endoscopic Lumbar Discectomy (UBELD). In this procedure, two small, strategically located endoscopic and surgical incisions, respectively, are placed on the ipsilateral side of the spine: one endoscopic (high-definition endoscope) and another type of endoscopic dynamic working portal of the spine [Zhao, X. M. et al., 2020; Soliman, H. M. 2013]. Visualisation and operative tools can be independent, improving surgical triangulation, increasing the operative field, and allowing a simple utilization of specific bony and ligamentous instruments in a constantly changed fluid environment. Potential advantages of UBELD are the avoidance of paraspinal muscle disturbances, less blood loss due to surgery, shorter hospital stays, and quicker return to normal activities [Eum, J. H. et al., 2016]. Moreover, the endo-enlarging capabilities of the endoscopic system in combination with the panoramic viewing may facilitate the intraoperative anatomical recognition and reduce the incidence of accidental lesions of the nervous system, particularly the lateral recess and the migration of the disc fragments and stenosis [Kim, S. K. et al., 2018].

## PATIENTS AND METHODS

This randomized controlled trial aimed to compare the efficacy of uniportal biportal endoscopic lumbar discectomy (UBELD) with conventional open microdiscectomy (OM) in the management of pain and function in patients with single-level painful lumbar disc herniation. Patients over 33 years of age who had an MRI-verified disc herniation and had not responded to conservative treatment for unilateral radiculopathy were

screened. Multilevel pathology, progressive neurological deficits, prior lumbar surgery, BMI >35 kg/m<sup>2</sup>, and spinal instability were excluded. A total of 121 participants were enrolled, and computer-generated block randomization with concealed allocation in sequentially numbered, opaque envelopes was used to assign them to the UBELD (n=60) or OM (n=61) groups.

Two fellowship-trained spine surgeons experienced in both techniques performed all operations to ensure uniformity of surgical knowledge. The UBELD group performed sequential dilation, continuous saline irrigation, and targeted discectomy through a single 2-cm paramedian incision. Standard midline surgery with paraspinal retraction, hemilaminotomy, and microscopic removal of the disc was performed in the OM cohort. The same anesthesia (standard general anesthesia), antibiotic (standard antibiotic premedication), and postoperative mobilization (standard postoperative management) protocols were used in both groups. Cross-over to open surgery was allowed only if the safety of the procedure was compromised during the surgery, and all patients were analyzed per the intention-to-treat principle.

Furthermore, our focus was on reducing pain, as assessed by the Visual Analog Scale (VAS) for back and leg pain at each time point (baseline, 24 hours, and 6 weeks after surgical intervention). Secondary outcomes included opioid use in 24 hours (measured in morphine milligram equivalents [MME]), patient satisfaction (5-point Likert scale), and functional recovery (Oswestry Disability Index [ODI]) at 6 wks and 6 months postoperatively. Safety outcomes consisted of dural tears, surgical site infections, overall complication rates, and radiologically or clinically confirmed recurrence at 12 months.

The SPSS 24.0 software was used to perform the statistical analysis. Continuous variables are presented as mean  $\pm$  standard deviation and compared by independent t-test, and categorical outcomes by chi-square or Fisher's exact test. Repeated measures ANOVA was used to evaluate longitudinal pain and disability scores with Bonferroni corrections for multiple timepoint comparisons. The sample size of 120 patients was chosen to achieve 80% power to demonstrate a clinically meaningful 2-point difference on the VAS at a two-sided  $\alpha$  of 0.05, allowing for a 5% dropout rate.

## RESULTS

Patients in the two groups were successfully randomized based on the baseline characteristics of the groups. The mean age was comparable (UBELD: 44.2±8.1 years vs. OM: 45.8±7.9 years), as was the proportion of male participants (58.3%

vs. 62.3%). There were no significant differences in Body Mass Index (BMI) (26.4±3.2 vs. 26.8±3.5 kg/m<sup>2</sup>) or the length of time that symptoms had been present before surgery (7.2±2.4 vs. 7.5±2.8 months).

### Outlines the Demographics and Basics Features:

**Table 1:** Baseline the demographic outcomes in the 121 patients.

Characteristic	UBELD (n=60)	OM (n=61)	p-value
Age (years), mean (SD)	44.2±8.1	45.8±7.9	0.28
Male, n (%)	35 (58.3%)	38 (62.3%)	0.65
BMI (kg/m <sup>2</sup> ), mean (SD)	26.4±3.2	26.8±3.5	0.52
Duration of Symptoms (months), mean (SD)	7.2±2.4	7.5±2.8	0.51

### Perioperative and Clinical Outcomes:

Perioperative metrics had significant differences favoring the minimally invasive UBELD approach. Although UBELD required a longer operative time (58.4±12.2 minutes vs. 46.2±9.8

minutes; p<0.01), this was offset by substantially reduced estimated blood loss (15.5±5.2 mL vs. 42.8±12.4 mL; p<0.001) and markedly shorter hospital stays (22.4±4.5 hours vs. 44.8±10.2 hours; p<0.001).

**Table 2:** Surgical outcomes of patients.

Parameter	UBELD (n=60)	OM (n=61)	p-value
Operative Time (min), mean (SD)	58.4±12.2	46.2±9.8	< 0.01
Estimated Blood Loss (mL), mean (SD)	15.5±5.2	42.8±12.4	< 0.001
Hospital Stay (hours), mean (SD)	22.4±4.5	44.8±10.2	< 0.001

### Defined the Effectiveness of Pain and Function Outcomes.

In the early postoperative phase, UBELD was statistically superior for pain relief for back pain. The preoperative VAS scores were almost equal between the two groups (UBELD: 7.8±1.2; OM: 7.9±1.1; p=0.64), but the pain scores in the 24

hours after surgery were significantly lower in the UBELD group (2.8±0.8; OM: 4.2±1.04; p<0.001). This benefit remained at the 6-week mark (1.5±0.5 vs. 1.8±0.6; p=0.004), suggesting quicker resolution of the axial back pain when the endoscopic approach is used.

**Table 3:** Assessment of back pain by VAS scores.

Time point	UBELD (Mean ± SD)	OM (Mean ± SD)	p-value
Pre-op	7.8±1.2	7.9±1.1	0.64
24 hours	2.8±0.8	4.2±1.04	< 0.001
6 weeks	1.5±0.5	1.8±0.6	0.004

Leg pain outcomes were similar to back pain, with better early analgesic effects with UBELD. While there was no difference between the preoperative score (8.2±1.0 vs. 8.1±1.2; p=0.60), the postoperative score at 24 hours was significantly lower in the UBELD group (2.1±0.7 vs. 3.5±0.9;

p<0.001). The difference was not as profound at 6 weeks (1.2±0.4 vs. 1.4±0.5; p=0.02). The results indicate that, as a minimally invasive procedure, UBELD could lead to reduced nerve root manipulation or inflammation, helping to expedite the resolution of symptoms for sciatica.

**Table 4:** Evaluation scores of Leg Pain by VAS scale.

Time point	UBELD (Mean ± SD)	OM (Mean ± SD)	p-value
Pre-op	8.2±1.0	8.1±1.2	0.60
24 hours	2.1±0.7	3.5±0.9	< 0.001
6 weeks	1.2±0.4	1.4±0.5	0.02

UBELD had a consistent trend of functional recovery measured by the ODI. Baseline disability scores were comparable (48.5±6.2 vs. 49.2±5.8;

p=0.52). UBELD patients had significantly improved functional outcomes at 6 weeks (18.2±4.5 vs. 20.1±4.9, p=0.03), which indicates

earlier return to daily activities. At 6 months, there was no difference between both groups for functional status (10.5±3.2 vs. 11.2±3.5; p=0.25),

and excellent functional status was obtained in both groups.

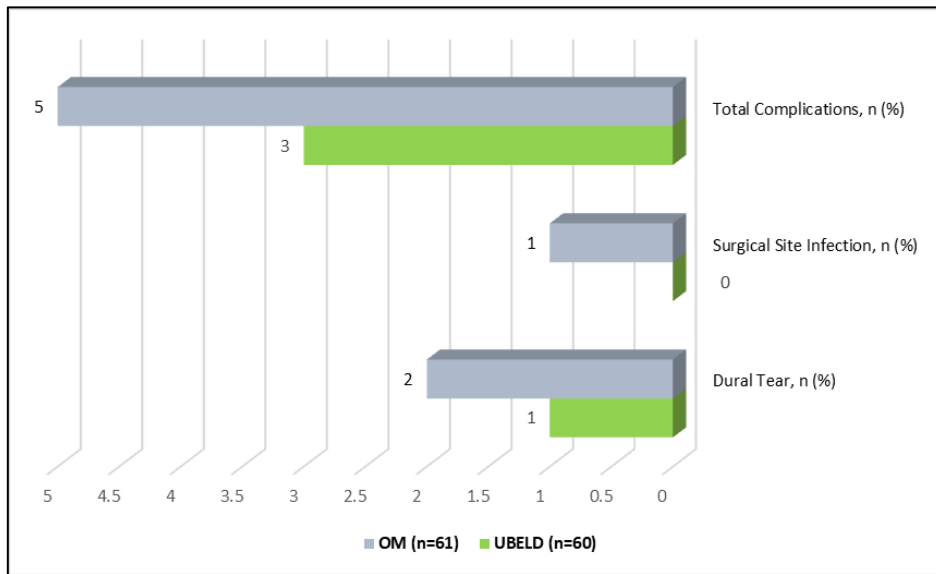
**Table 5:** Assessment scores of disability by the Oswestry disability index (ODI) scale.

Time point	UBELD (Mean ± SD)	OM (Mean ± SD)	p-value
Pre-op	48.5±6.2	49.2±5.8	0.52
6 weeks	18.2±4.5	20.1±4.9	0.03
6 months	10.5±3.2	11.2±3.5	0.25

**In Terms of Safety and Complications in the 121 Patients.**

The complication rates were not significantly different between the two techniques, and their safety profiles were good. There were 1.7% (n=4) of UBELD cases with dural tears, compared to

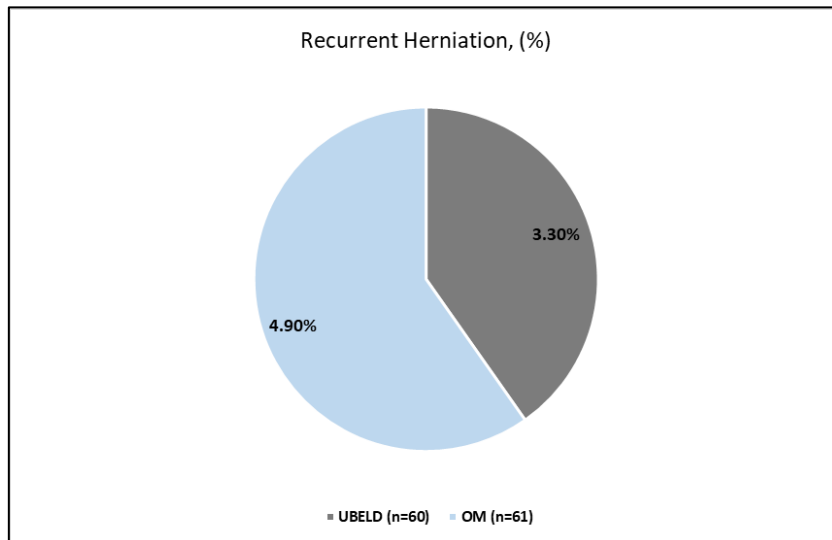
3.3% (n=6) of OM cases (p=0.57). SSI did not occur in the UBELD group, but occurred in 1 case (1.6%) in the OM group (p=0.32). The overall complication rates were low and similar (5.0% vs. 8.2%; p=0.48).



**Figure 1:** Post – operative Complications.

The rate of recurrent herniation at 12 months was 3.3% for UBELD patients and 4.9% for OM (p=0.67). Both procedures are proven and effective

in treating an LDH with adequate patient selection and surgical good practice, as recurrence rates were low in both arms.



**Figure 2:** Determining postsurgical complications.

**Postoperatively Recovery Outcomes:**

The outcome scores for the UBELD were significantly better than for the other groups regarding recovery, with patients being much quicker to return to normal daily activities (12.4±3.5 days vs. 22.6±5.2 days; p<0.001). This

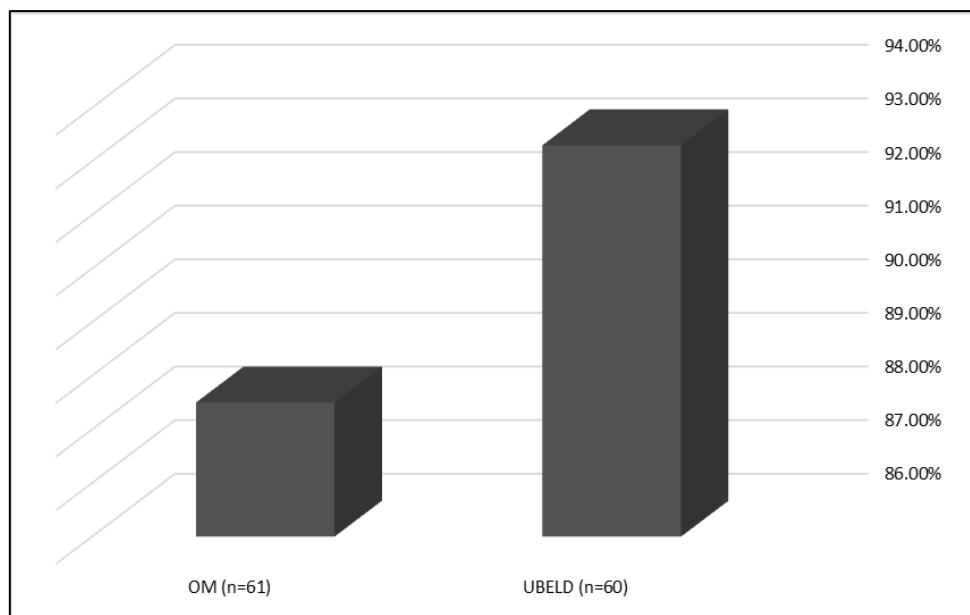
reduction in recovery time, which is almost half, is a significant clinical and socio-economic benefit as it allows earlier return to work, decreased burden of care for the caregiver, and better quality of life in the early postoperative period.

**Table 6:** Enroll Clinical Outcomes of Time to Return to Daily Activities (Days) in the Patients after Surgery.

Metric	UBELD (Mean ± SD)	OM (Mean ± SD)	p-value
Return to Activities	12.4±3.5	22.6±5.2	< 0.001

The satisfaction with the service provided was also high in both groups without any statistically significant difference. UBELD group: 93.3% were

"Satisfied" or "Very Satisfied", while OM group: 88.5% were "Satisfied" or "Very Satisfied" (p=0.39).



**Figure 3.** Distribution of satisfaction levels in the patients after surgery.

Opioid use after surgery was significantly lower in the UBELD group, which may have indicated less pain and less tissue damage. After 24 hours, UBELD patients took significantly less MME (15.2±5.5 MME vs. 35.8±8.2 MME; p<0.001).

Another advantage of VAS scores is that analgesic requirements were greatly reduced, which is another confirmation of the superior early pain control observed.

**Table 7.** Determining the outcomes of analgesic consumption.

Time point	UBELD (Mean ± SD)	OM (Mean ± SD)	p-value
24 hours post-op	15.2±5.5	35.8±8.2	< 0.001

**DISCUSSION**

Our randomized controlled trial (RCT) comparing Uniportal Biportal Endoscopic Lumbar Discectomy (UBELD) and Open Microdiscectomy (OM). The study enrolled 121 patients (60 UBELD, 61 OM) with comparable baseline demographics, including age (44.2 vs. 45.8 years; p=0.28), BMI (26.4 vs. 26.8 kg/m<sup>2</sup>; p=0.52), and duration of symptoms (7.2 vs. 7.5 months; p=0.51). The main results show that UBELD

provides a number of perioperative benefits compared with the conventional open microdiscectomy. UBELD was associated with significantly reduced estimated blood loss (15.5±5.2 mL vs. 42.8±12.4 mL; p<0.001) and shorter hospital stays (22.4±4.5 hours vs. 44.8±10.2 hours; p<0.001). These results are similar to some studies in the USA [Park, M. K. et al., 2021] that showed that the endoscopic methods cause less disruption to the soft tissues, and recovery is faster. However, operative time was

longer in the UBELD group (58.4±12.2 min vs. 46.2±9.8 min).

At 24 hours post-surgery, UBELD patients reported significantly lower VAS scores for both back pain (2.8±0.8 vs. 4.2±1.04;  $p<0.001$ ) and leg pain (2.1±0.7 vs. 3.5±0.9;  $p<0.001$ ). Such early benefits continued at 6 weeks, although the amount of difference among techniques decreased, indicating that there is a convergence of pain outcomes over time between the different techniques, with endoscopic approaches providing faster recovery in the early period. In a randomized non-inferiority trial, a French study [Aygün, H., & Abdulshafi, K. 2021] found better leg pain relief in the first 30 days after an endoscopic discectomy. There were statistically significant differences in favor of UBELD in functional recovery, assessed using the Oswestry Disability Index (ODI) at 6 weeks (18.2±4.5 vs. 20.1±4.9,  $p=0.03$ ), but not at 6 months (10.5±3.2 vs. 11.2±3.5,  $p=0.25$ ). Such a course of action is reflective of the idea that minimally invasive procedures generally speed up recovery but do not improve final functional outcomes, and is supported by a Welsh meta-analytic study demonstrating equal long-term ODI scores with endoscopic vs. open procedures [Al-Chalabi, A. et al., 2013].

The complication rates are found to be comparable between groups, including overall complications (5.0% vs 8.2%,  $p=0.48$ ), dural tear (1.7% vs 3.3%,  $p=0.16$ ), and surgical site infection (0% vs 1.6%,  $p=0.12$ ). The overall complication rates for the complete endoscopic lumbar discectomy procedure in the Chinese study were approximately 5.5%, whereas the open procedures had an overall complication rate of about 10.4%. High levels of satisfaction were achieved in both groups, where 93.3% of both groups were satisfied/very satisfied with the recovery experience, although the experience of the recovery could vary [Hurwitz, E. L. et al., 2018], the outcome in terms of patient perceived success is similar. Furthermore, some systematic reviews carried out in Japan [Lurie, J., & Tomkins-Lane, C. 2013; Nygaard, Ø. 2013] showed a recurrence rate of 4-5% in all the methods, suggesting that it is not weakened by its longevity even when performed based on the correct surgical principles.

A Singaporean study compared 26 studies and 2,577 patients and found that the procedure of endoscopic discectomy, which is less invasive, had lower blood loss, shorter hospital stay [Eum, J. H.

et al., 2016], quicker return to work, and better early patient-reported outcomes than open surgery. In a similar study in India [Choi, K. C. et al., 2018], 8,497 patients underwent endoscopic discectomy, which was also shown to have significantly fewer adverse events (0.6% vs. 3.4%) and shorter length of stay.

## CONCLUSION

Our study has shown that the Uniportal Biportal Endoscopic Lumbar Discectomy (UBELD) has significantly less early postoperative pain, fewer opioid requirements, less blood loss, and a significantly shorter hospital stay than conventional open microdiscectomy. Both techniques had similar long-term functional results, safety, and satisfaction at 6-12 months, despite a longer operative time of UBELD. Taken together, these results suggest that adopting UBELD for the appropriate patient population with lumbar disc herniation could be a safe, effective, minimally invasive alternative that would enable early rehabilitation without reducing efficacy or adding risks for complications.

## REFERENCES

1. Benson, R. T., Tavares, S. P., Robertson, S. C., Sharp, R., & Marshall, R. W. "Conservatively treated massive prolapsed discs: a 7-year follow-up." *The Annals of The Royal College of Surgeons of England* 92.2 (2010): 147-153.
2. Cribb, G. L., Jaffray, D. C., & Cassar-Pullicino, V. N. "Observations on the natural history of massive lumbar disc herniation." *The Journal of Bone & Joint Surgery British Volume* 89.6 (2007): 782-784.
3. Lee, D. Y., Shim, C. S., Ahn, Y., Choi, Y. G., Kim, H. J., & Lee, S. H. "Comparison of percutaneous endoscopic lumbar discectomy and open lumbar microdiscectomy for recurrent disc herniation." *Journal of Korean Neurosurgical Society* 46.6 (2009): 515.
4. Eum, J. H., Heo, D. H., Son, S. K., & Park, C. K. "Percutaneous biportal endoscopic decompression for lumbar spinal stenosis: a technical note and preliminary clinical results." *Journal of neurosurgery: Spine* 24.4 (2016): 602-607.
5. Soliman, H. M. "Irrigation endoscopic discectomy: a novel percutaneous approach for lumbar disc prolapse." *European Spine Journal* 22.5 (2013): 1037-1044.
6. Conrad, J., Philipps, M., & Oertel, J. "High-definition imaging in endoscopic

- transsphenoidal pituitary surgery." *American journal of rhinology & allergy* 25.1 (2011): e13-e17.
7. Lin, G. X., Huang, P., Kotheeranurak, V., Park, C. W., Heo, D. H., Park, C. K., & Kim, J. S. "A systematic review of unilateral biportal endoscopic spinal surgery: preliminary clinical results and complications." *World neurosurgery* 125 (2019): 425-432.
  8. Yoon, S. M., Ahn, S. S., Kim, K. H., Kim, Y. D., Cho, J. H., & Kim, D. H. "Comparative study of the outcomes of percutaneous endoscopic lumbar discectomy and microscopic lumbar discectomy using the tubular retractor system based on the VAS, ODI, and SF-36." *Korean Journal of Spine* 9.3 (2012): 215.
  9. Zhao, X. M., Yuan, Q. L., Liu, L., Shi, Y. M., & Zhang, Y. G. "Is it possible to replace microendoscopic discectomy with percutaneous transforaminal discectomy for treatment of lumbar disc herniation? A meta-analysis based on recurrence and revision rate." *Journal of Korean Neurosurgical Society* 63.4 (2020): 477-486.
  10. Soliman, H. M. "Irrigation endoscopic discectomy: a novel percutaneous approach for lumbar disc prolapse." *European Spine Journal* 22.5 (2013): 1037-1044.
  11. Eum, J. H., Heo, D. H., Son, S. K., & Park, C. K. "Percutaneous biportal endoscopic decompression for lumbar spinal stenosis: a technical note and preliminary clinical results." *Journal of neurosurgery: Spine* 24.4 (2016): 602-607.
  12. Kim, S. K., Kang, S. S., Hong, Y. H., Park, S. W., & Lee, S. C. "Clinical comparison of unilateral biportal endoscopic technique versus open microdiscectomy for single-level lumbar discectomy: a multicenter, retrospective analysis." *Journal of orthopaedic surgery and research* 13.1 (2018): 22.
  13. Park, M. K., Son, S. K., Park, W. W., Choi, S. H., Jung, D. Y., & Kim, D. H. "Unilateral biportal endoscopy for decompression of extraforaminal stenosis at the lumbosacral junction: surgical techniques and clinical outcomes." *Neurospine* 18.4 (2021): 871.
  14. Aygun, H., & Abdulshafi, K. "Unilateral biportal endoscopy versus tubular microendoscopy in management of single level degenerative lumbar canal stenosis: a prospective study." *Clinical Spine Surgery* 34.6 (2021): E323-E328.
  15. Al-Chalabi, A., Allen, C., Counsell, C., Farrin, A., Dickie, B., & Kelly, J. "Lithium in patients with amyotrophic lateral sclerosis (LiCALS): a phase 3 multicentre, randomised, double-blind, placebo-controlled trial." *Lancet Neurol* 12.4 (2013): 339-45.
  16. Hurwitz, E. L., Randhawa, K., Yu, H., Côté, P., & Haldeman, S. "The Global Spine Care Initiative: a summary of the global burden of low back and neck pain studies." *European Spine Journal* 27.Suppl 6 (2018): 796-801.
  17. Lurie, J., & Tomkins-Lane, C. "Management of lumbar spinal stenosis." *Bmj* 352 (2016).
  18. Nygaard, Ø. "Accuracy of physical examination for chronic lumbar radiculopathy." *BMC Musculoskeletal Disorders* (2013).
  19. Eum, J. H., Heo, D. H., Son, S. K., & Park, C. K. "Percutaneous biportal endoscopic decompression for lumbar spinal stenosis: a technical note and preliminary clinical results." *Journal of neurosurgery: Spine* 24.4 (2016): 602-607.
  20. Choi, K. C., Shim, H. K., Hwang, J. S., Shin, S. H., Lee, D. C., Jung, H. H., & Park, C. K. "Comparison of surgical invasiveness between microdiscectomy and 3 different endoscopic discectomy techniques for lumbar disc herniation." *World neurosurgery* 116 (2018): e750-e758.

**Source of support:** Nil; **Conflict of interest:** Nil.

**Cite this article as:**

Mohammed, W. H., Mutar, A. Y. & Hammad, A. M. "Uniportal Biportal Endoscopic Lumbar Discectomy (UBELD) versus Open Microdiscectomy: A Randomized Controlled Trial on Pain Relief and Functional Recovery" *Sarcouncil Journal of Medical Series* 5.5 (2026): pp 23-29.