

## Ultrasound Imaging with Birads Classification: A Reliable Diagnostic Tool for Breast Lesions in Women with Confounding Factors

Sharafat Ali<sup>1</sup>, Muhammad Abdullah<sup>2</sup>, Mahnoor Fatma<sup>3</sup>, Nasreen Fatima<sup>4</sup>, Abdul Sala<sup>5</sup>, Alina Jamro<sup>2</sup> and Lajwar Hayat<sup>2</sup>

<sup>1</sup>Department of Medical Imaging Technology Riphah international University Faisalabad

<sup>2</sup>Medical Imaging Technology Time Institute Multan

<sup>3</sup>Riphah international university

<sup>4</sup>Chemistry Department University of Baltistan Skardu

<sup>5</sup>Wazir Muhammad Institute of Allied Health Sciences, Gandhara University Peshawar

**Abstract:** OBJECTIVE: This study investigates the accuracy of ultrasound imaging paired with BI-RADS classification in diagnosing breast lesions in women, taking into account the influence of confounding factors such as breast density and tissue inflammation. METHODS: A group of 100 women of diverse age ranges and marital statuses participated in this research. Data was collected on indications for medical visits, duration and nature of symptoms, breast composition, echo patterns, density, presence of tissue inflammation, and BI-RADS classification. These variables were analyzed to assess effectiveness of BI-RADS classification amidst the confounding factors. RESULTS: The study found that 46% of participants were over 35 years old and 78% were married. The most common reasons for their medical consultation were tenderness (29%), pain (15%), and lumps (18%). Breast composition was largely heterogeneous (55%), with hyperechoic (43%) and hypoechoic (33%) echo patterns, and predominantly heterogeneously dense breasts (69%). Inflammation of tissues or mastitis was detected in 25% of cases. BI-RADS classification placed 27% of cases in category 2, 20% in category 1, and 17% in category 4. Pathological diagnosis was unilateral in 80% and bilateral in 20% of cases. CONCLUSION: The findings suggest that ultrasound imaging with BI-RADS classification is an effective method for diagnosing the breast lesions, even when confounding factors such as breast density and tissue inflammation are present. Further refinement of the BI-RADS classification is advised to enhance diagnostic outcomes in these contexts.

**Keywords:** BIRADS Classification, Ultrasound, Tissue Inflammation, Breast Density, Breast Lesion.

### INTRODUCTION

The breast is a glandular organ (skin glands / apocrine glands) of ectodermal origin located on the chest. The human female breast contains mammary glands are made up of connective tissues, and fats. The function of mammary glands is the production and secretion of milk. It is covered by subcutaneous fats and has a network of ducts that converge on the nipple. The breast tissues have distinct globular shapes according to their function. The breast is an organ that plays a pivotal role in human survival as the mother feeds and gives life to a newborn. The human breast faces many different phases as the female body grows up.

The function of breastfeeding is very unique and distinctive as it has a deep effect on two lives. The occurrence of diseases is also very high in this organ. Further human females especially those residing in third world countries have poor consideration of health same way they completely ignore even mild to moderate symptoms of breast diseases. The consequences are drastic leading to the highest mortality and morbidity among females.

One in three females (30%) will suffer from any breast disease. Breast cancer is the second leading

cause of death in the world after lung cancer. A WHO study from 2022 puts breast cancer at 670000 deaths worldwide. It was the most diagnosed cancer among females in 157 of the 185 surveyed countries in 2022. No risk factors aside from sex and age are really known. The risk of death from breast cancer is 1 in 40, which is 2.5%, according to the American Cancer Society (World Health Organization, 2024). Survival is dependent on early detection, and it is recommended that women aged 30-40 should conduct self-physical examinations monthly followed by a comprehensive examination annually, while women aged 40-50 and females 30-40 with a history of breast disease either clinically or in the immediate family should have examinations biannually. Success stories in medicine regard early prognosis and treatment. Advanced technologies and therapeutics have emerged with the marking of safe patient survival.

Diagnostic imaging modalities always play a significant role in the precise diagnosis of diseases and accurate metastatic / risk prediction. The advanced noninvasive modalities for breast imaging are mammography (imaging using ionizing X-rays) ultrasound (using sound waves) and MRI (using magnetic field and radio waves).

Among all modalities discussed above ultrasound is considered safest and recommended due to its efficacy, accessibility, and noninvasive nature. However certain factors affect its precision like breast density, predisposing factors like inflammation and patient age, etc.

We aim to rule out the efficacy of ultrasound in diagnoses of breast lesions despite confounding factors such as infections, inflamed breasts, mastitis, etc.

## BACKGROUND

Breast ultrasound is essential in the diagnosis of mammary lesions. It is the primary test for evaluating palpable foreign masses in patients younger than 30. In addition, breast ultrasound is routinely used to characterize abnormal mammogram findings as either solid or cystic and provide guidance for image-guided breast intervention procedures (Khan, P. *et al.*, 2023).

These early researchers and many others would consolidate scientific forces for the evolution of breast ultrasound as an imaging diagnostic modality. Much later, sometime in the 1970s, breast ultrasound gained popularity in the clinical setting, especially in the United States and Asia. During that period, Japanese researchers, Kobayashi *et al.*, published numerous papers delineating various features which could distinguish benign breast disease from malignant disease that introduced the classical acoustic shadowing descriptor associated with breast malignancy. The advancements during late 80s and early 90s in color Doppler ultrasound aided in augmenting the B-mode grayscale images, further increasing the ability to distinguish malignant from benign findings. Several research studies are aimed towards investigating the application of AI algorithms to breast ultrasound to improve image interpretation, automate lesion detection, and strategize toward higher accuracy (Rapelyea, J. A., & Marks, C. G. 2017).

Breast cancer is the most common type of cancer occurring in females worldwide with approximated one million new cases every year and is the next leading cause of death in females. Breast cancer is the commonest form of cancer and an important contributor to the cancer mortality rate among women in Pakistan. In Pakistan, an incidence of 1 out of 9 is reported among women afflicted with Breast cancer. Majorly responsible for this dire

mortality rate is a lack of awareness and screening programs that can help early detection, coupled with lack of resources to avail the proper diagnostic facilities. The incidence rate of breast cancer in Pakistan is about 2.5 times compared to India and Iran. Pakistan holds the highest incidence rate of breast carcinoma in Asia. Every year in Pakistan, a minimum of 90,000 women are affected by breast cancer. Based on the population-adjusted cancer data for South Asia, Pakistan has the highest age-adjusted breast cancer incidence, at 69 per 100,000 (Asif, H. M. *et al.*, 2014). Overall, addressing social determinants of health and equitable access to healthcare services for the early detection of breast lesions is paramount in closing disparities in breast carcinoma and improving outcomes for appropriate treatment for women in Pakistan. The most recent data from the Shaukat Khanum Memorial Cancer Hospital shows that breast cancer constitutes 21.5% of all cancers in Pakistan and 45.9% of cancers in female patients.

## Anatomy of the breast:

### Breast composition:

The breast is composed of fibro glandular tissue and ductal tissue that is surrounded by the superficial and deep fascia, intermixed with the fat, and covered by the skin. The supportive fibrous bands that course between the superficial and deep fascial layer are Cooper ligaments. The breast extends from the 2<sup>nd</sup> rib to the 6<sup>th</sup> rib, between the sternum to the axilla marked as medial and lateral boundaries. Glandular parenchyma is approximately comprised of 15 to 20 lobes that terminate into nipples. Each areola is surrounded by Montgomery glands which are small oil glands that protect the nipple by providing lubrication (Sanders, R. C., & Hill, B. 2006).

Between the skin and the chest wall, the breast is subdivided by fascial planes into three layers: the subcutaneous fat (pre-mammary layer) zone, the mammary (parenchymal) zone, and the retro-mammary fat zone (Carr-Hoefer, C. 2003).

### Arterial supply to the breast:

These are the three arteries supplying blood to the breast: lateral mammary branch of lateral thoracic artery, anterior cutaneous branch of internal mammary artery, and branches from 2<sup>nd</sup> to 6<sup>th</sup> intercostal arteries (Sanders, R. C. & Hill, B. 2006).

### Venous drainage of the breast:

The veins lie within the internal thoracic and

axillary basal vein systems. They drain the breast and enter muscle layer, fascia and intercostal spaces in equal ranges. The veins form anastomotic circular structures around the base of the nipple at the backside of the papilla referred to as circulus venous. The small veins take this blood to the circumference of the gland before terminating into axillary and internal mammary veins (Sanders, R. C. & Hill, B. 2006).

#### **Lymphatic drainage of the breast:**

Lymphatic drainage is important because by this route malignant disease can spread to other areas of body; however it is important because of lactating breasts. The majority of lymphatic drainage is from axillary lymph nodes, present in axilla. Cancer cell mostly spread through axillary lymph nodes. From medial aspect of breast, lymphatic drainage into internal mammary lymph nodes and parasternal lymph nodes that present along internal mammary vessels and sternum respectively. Lymph may drain into supraclavicular lymph nodes from the upper outer quadrant of the breast. (Sanders, R. C. & Hill, B. 2006).

#### **Sonographic Appearance:**

The skin appears hyperechoic in ultrasound being derived from a thickness of 2 mm. By ultrasound, it is possible to detect the pre-mammary, mammary (majority breast cancer detected), retro-mammary layers. There is hypoechoic subcutaneous fat seen anterior to pre-mammary fascia. Cooper ligament which courses between superficial and deep subcutaneous fat may seem hyperechoic. Posterior structures include Pectoralis muscle, ribs, and lungs (Sanders, R. C. & Hill, B. 2006).

#### **Importance of BI-RADS in ultrasound imaging:**

Breast cancer is a common cause of cancer deaths among women and holds 5th place among cancers in men: lung, stomach, colon, and liver. However, breast cancer is more prevalent among post-menopausal women and even younger females. It is the leading cause of morbidity and mortality in women around the world and a serious challenge to their health, both in developed and developing countries, including Pakistan. Pakistan has the highest breast cancer rates in Asia. Breast cancer also affects younger females, who tend to have a worse prognosis. The Age-Standardized Prevalence Rate for breast cancerous conditions was found to be: 43.3/100,000 women worldwide, 50.3/100,000 in Pakistan in 2012 (Malik, N., Rauf,

M., & Malik, G. 2020).

The routine imaging modalities for detecting, classifying and treating breast lesions are ultrasound and mammography. Commonly, conventional ultrasound is the first-choice imaging modality for examining abnormal findings in palpation in the young female population (<30 years), is routinely undertaken in mammographic further classification of abnormalities as solid or cystic, and gives guidance for image-guided breast procedures. But it is not always conclusive for the biological type of the lesion. With the introduction of the BI-RADS for sonography in the year 2003, the sonographic BI-RADS lexicon/classificatory system has proved to be reliable and also to perform quite well in assessing one's risk for malignancy (Kim, J. Y. *et al.*, 2015). The Breast Imaging Reporting and Data System (BI-RADS) is a classification for sonography features such as shape, margins, lesion boundary, orientation, echogenicity, posterior acoustic characteristics, and associated features. So the conclusive assessment and recommendations may give all this but based on multiple features (Kim, E. K. *et al.*, 2008). The development of the BI-RADS system was due to the American College of Radiology (ACR), in order to generate a common language and pattern to allow the radiologists to communicate breast imaging results with clinicians and patients. The BI-RADS system encompasses both a lexicon of standard terms as well as a stratification system that places breast imaging findings into categories of different levels of suspicion for malignancy. While some controversy still exists as to its value regarding the use of US to determine the likelihood of malignancy of solid breast masses, a number of studies have suggested that the sonographic appearance will be useful in differentiating benign solid breast masses from malignant ones (Lee, H. J. *et al.*, 2008). Several research studies have emphasized the importance of BI-RADS in ultrasound imaging. Study published has revealed that BI-RADS application in ultrasound imaging improves the accuracy of breast cancer diagnosis while reducing false positives (Malik, N., Rauf, M., & Malik, G. 2020). According to another study reported in the Journal of Radiology, the BIRADS classification was a great diagnostic indicator for malignancy in breast lesions detected by ultrasound (Lazarus, E. *et al.*, 2006). It was further explored that Ultrasound BI-RADS classification being an efficient and legitimate diagnostic tool, having 75% sensitivity and 82% specificity for establishing a diagnosis in

breast lumps, should minimize the burden of unnecessary biopsies as concluded from the study conducted in Pakistan. BIRADS in ultrasound significantly impacts the standardization of interpretation and reporting, thereby enhancing communication and improving patient care. BI-RADS usage in ultrasound imaging forms the basis for research studies confirming accurate diagnosis and effective management towards optimal patient outcome.

The potential for diagnostic accuracy with ultrasound imaging in BIRADS classification in detecting breast lesions in women, notwithstanding confounding factors of breast density and tissue inflammation, are under study. The goal of this study is to see how dependable and efficient ultrasound imaging with BIRADS classification can be in the diagnosis of breast lesions while assessing the influence of breast density and tissue inflammation factors on diagnostic accuracy, as well as therefore ruling out the benign versus malignant nature of breast lesions. The study aims to improve the impact on early detection and management of breast lesions leading to better patient outcomes. "So can the ultrasound imaging with BIRADS classification diagnose breast lesions in women accurately amidst possible confounding factors like breast density and tissue inflammation?"

This research aims to evaluate the effectiveness of ultrasound in diagnosing breast lesions, focusing on its reliability as a highly accessible imaging tool. By examining factors like breast density and tissue inflammation, which are prevalent in a large portion of the community, the study seeks to assess how these confounding factors affect ultrasound accuracy. Additionally, it will explore the correlation between previous breast conditions and future diagnoses, providing insights into the role of ultrasound in detecting breast abnormalities. The significance of this research lies in its potential to enhance diagnostic accuracy and clarify the role of ultrasound in overcoming challenges posed by density, inflammation, age, and lactation phases. The findings will contribute to a deeper understanding of ultrasound's effectiveness, offering a non-invasive, reliable diagnostic option with improved patient accessibility and care.

## LITERATURE REVIEW

Breast cancer is the leading cause of death related to cancer in women worldwide, early detection and accurate diagnosis of breast cancer is crucial for

effective treatment and survival of patients. In recent studies, globally 2,308,897 cases were reported of breast cancer, leading it to 2<sup>nd</sup> place in overall cancer ranking, and 665,684 cases were reported of mortality due to breast cancer (Bray, F., Laversanne, M. *et al.*,2024). Breast ultrasound is multimodal and can map blood flow and mechanical properties of the tissue using the BIRADS categorization system. Consistent improvements in image quality over the years have expanded the role of ultrasound in the detection and diagnosis of breast pathology, and sonography is routinely used as an adjunct to X-ray mammography (Sehgal, C. M. *et al.*,2006). This literature review aims to evaluate the existing evidence on the accuracy of ultrasound imaging with BIRADS classification in diagnosing breast lesions, despite potential confounding factors

### Breast Lesion and BIRADS Classification:

Breast lesions are the abnormalities present in breast tissue that can be benign or malignant according to their complexity. BI-RADS classification is a standardized system used to categorize the breast lesions diagnosed using any modality based on their likelihood of malignancy (Sickles, E. A. 2013). A study concluded that the BI-RADS categorization system was a reliable predictor of malignancy in screening ultrasonography-detected breast lesions, with varied degrees of malignancy observed in different categories (Malik, N., Rauf, M., & Malik, G. 2020).Ultrasound helps to evaluate the breast lumps with BI-RADS classification. For categorizing focal breast lesion, the American college of Radiology has revealed BI-RADS classification on ultrasound (Gokhale, S. 2009).

Ultrasound is used as an effective method to differentiate cystic breast lesions from solid breast lesions. It also provides helpful insights about the nature and extent of breast lesions with the help of BI-RADS classifications. BI-RADS provides standardized breast imaging terminologies, assessment structure, and classification system and report organization for ultrasound, mammography and MRI of breast. Ultrasound classifies some solid breast lesions as benign lesion more accurately that allow follow-up instead of biopsy (Fisher, M. P. R. 2021).

### Breast Density:

Breast density is a potential confounding factor that may affect the accuracy of ultrasound imaging with the BI-RADS classification system.



Mammographic density is a well-defined risk factor for breast carcinoma and having extremely dense breast tissue is associated with one-to six-fold increased risk of breast malignancy. Research investigates the association between mammographic density and breast cancer risk using digital mammography. Outcomes show extremely dense breast tissue (BI-RADS density D) increases the breast malignancy chances by 2.11-fold compared to the scattered dense tissue (BI-RADS density B) (Bodewes, F. T. H. *et al.*, 2022). An investigation done by meta-analysis of 21 studies found that mammography is ineffective in detecting breast cancer in dense breasts. Supplemental ultrasound (US) showed added detection sensitivity but slightly decreased diagnostic specificity (Yuan, W. H. *et al.*, 2020). Ultrasound is useful in detecting breast diseases in women with high breast density as compared to mammography. There is higher risk of breast cancer in dense breast women as compared to the less dense breast women. Ultrasound is an operator dependent and covers that whole area of dense breast easily analogous to mammography (O'Flynn, E. A. *et al.*, 2017).

#### **Tissue Inflammation:**

Tissue inflammation is another confounding factor that can mimic breast lesions, leading to false positives or false negative findings. Imaging features of benign and malignant inflammatory conditions often overlap which may cause diagnostic confusion leading to misdiagnosis (Jung, S. L. *et al.*, 2018). An analysis was performed of 526 studies, out of which 26 were eligible for inclusion. Ultrasound had a high sensitivity and specificity of 80.1% and 88.4%, respectively despite the presence of tissue inflammation in some cases, supporting its potential in low-resource settings (Sood, R. *et al.*, 2019). Ultrasound is demonstrated as an effective tool for diagnostic challenges of breast inflammation. Limitation to use mammography for diagnostic purpose of breast inflammation as it cannot compress the breast due to its inflammatory conditions. Breast inflammation is generally associated to edema and skin thickness. For such breast issues, ultrasound is useful as diagnostic and

therapeutic imaging modality (Febery, A., & Bennett, I. 2019).

#### **Accuracy of Ultrasound with BI-RADS Classification:**

Investigation findings have consistently demonstrated the accuracy of ultrasound imaging with the BI-RADS classification system in diagnosing breast lesions in the general population. The research assessed the accuracy of categorizing breast ultrasound diagnosis based on carcinoma scoring using the sonographic breast imaging-reporting and data system (BI-RADS). Results showed that the BI-RADS breast ultrasound had a high accuracy rate, comparable to that obtained by the mammography, with 1.2% malignant findings in Category 3 of BI-RADS (Rosenberg, R. D. 2009).

A study published found that the use of BI-RADS in ultrasound imaging improved the accuracy of breast cancer diagnosis and reduced the number of false-positive results (Malik, N., Rauf, M., & Malik, G. 2020). A study compared the ultrasonography and mammography diagnostic accuracy and breast imaging-reporting and data system (BI-RADS) classification versus breast core needle biopsy (CNB) findings in differentiating breast lesions. Outcomes showed that combined mammography and ultrasound had higher accuracy rates and an acceptable positive predictive value in diagnosing breast masses using BIRADS classification (Ghaemian, N. *et al.*, 2021).

#### **RESEARCH METHODOLOGY**

Pakistan has the highest incidence of breast cancer among Asian countries. One in nine women is at risk of being diagnosed with breast cancer during their lifetime. According to the International Agency of Research on Cancer 2018 report, 34,066 new cases of breast cancer have been reported in Pakistani women. We have carried out research to find out ultra sound accuracy in breast imaging despite presence of confounding factors like breast density and tissue inflammation. As ultrasound is easily accessible and non-invasive technique.

Research Framework

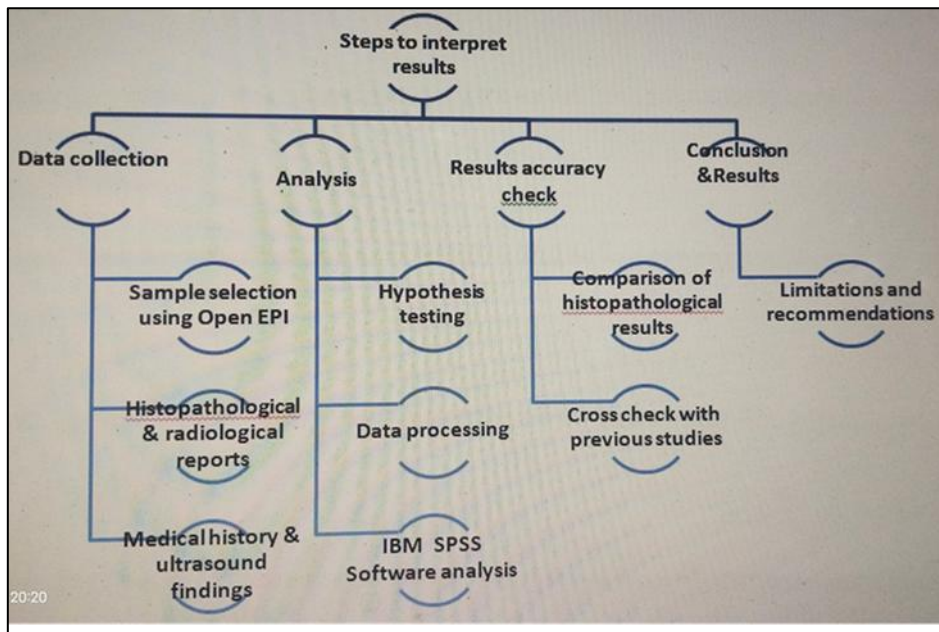


Figure 1: research framework

Data Collection

Data was obtained by visiting government hospitals of Faisalabad. It was done in prior permission from university as well from hospital. Most of ultrasonography performed on Toshiba high resolution ultrasound machine. Specialized ultrasound specialist / consultant opinion was included. Informed consent form and patients confidentiality was our first priority. Raw data was then processed further for further evaluation. Here is rough sketch showing overall key points of our research design.

Data processing

We have used the IBM SPSS statistics. It is a software platform that offers advanced statistical analysis, machine learning algorithms, and text analysis. It is easy to use making it accessible for research purposes. SPSS statistics can read and write data from ASCII text files. Data analysis will be carried out in the following way and results will be generated. Here is the diagrammatic demonstration of our adopted processing techniques.

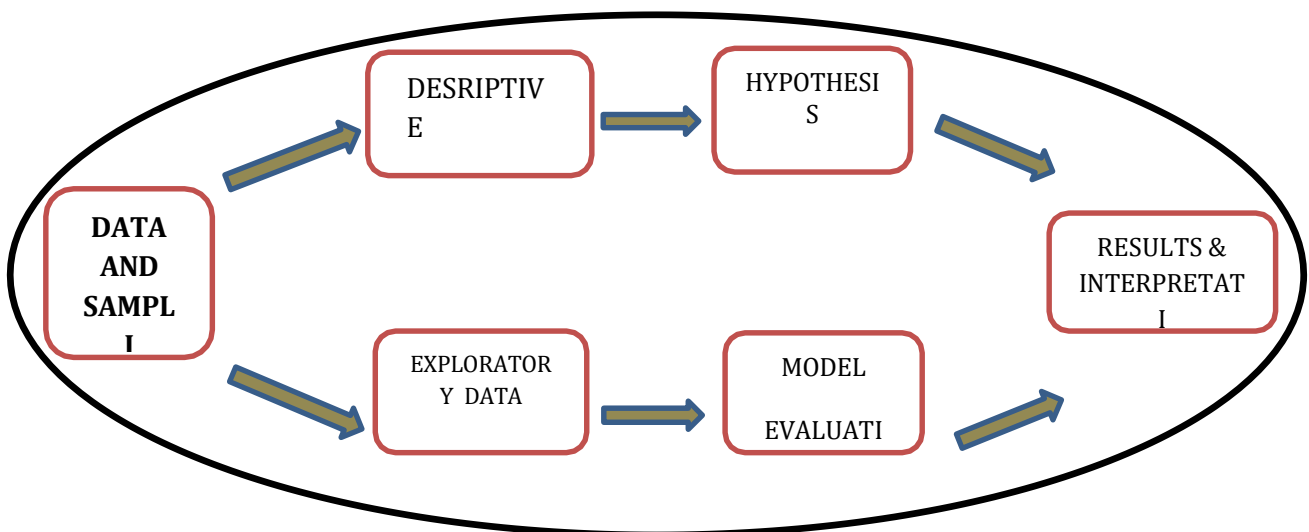


Figure 2: Data processing

## Tools and Technology

### Imaging equipment

High frequency linear array transducers 10 - 18 MHz for breast imaging have been used. Advanced equipped with specialized standard, protocols of breast imaging, Ultrasound imaging machines were used for acquiring images.

Ultrasound has been performed by specialized radiologists for the accuracy of results. High-resolution Toshiba ultrasound machine will be used. The spatial and contrast resolution of breast ultrasound must be first-rate. For breast ultrasound, Broadband and high-frequency linear electronically focused probes present the best combination of spatial and contrast resolution. The axial and lateral components of spatial resolution must be excellent.

### Proposed Method

We have adopted an Observational Study design. Our study carries a Cross-Sectional Study design to assess the prevalence of a condition or exposure at a specific point in time as we examine the prevalence of breast lesions using ultrasound and BIRADS classification in a specific population.

### Sampling technique

By adopting a cross-sectional population-based study we assessed disease estimates by using complex probabilistic sampling.

### Study Setting and Duration:

We have performed our study in the Radiology Department of the government hospital of Faisalabad e.g. Allied Hospital, District Headquarters Hospital, And Safi Teaching Hospital). Here we will assess the patient's history coming to the radiology department with complaints of breast pain and screen out ultrasound reports. Further results will be strengthened by surveying in targeted population and filling out the self-constructed questionnaire form.

Our research has taken 4 months to analyze results here is a diagrammatic representation of our estimated work plan.

### Statistical evaluation:

SPSS has been used for statistical analysis.

### Sample size:

A sample size of 100 females has been selected with inclusion and exclusion criteria as follows.

### Inclusion Criteria:

- Females of age group 15-45
- Has visited the hospital or health care for breast issues
- Diagnosed with breast lesions (benign or malignant).

### Exclusion Criteria:

- Inability to provide informed consent.
- Women aged 46 or above
- Has zero visit history of medical health care.

### Outcome Variables:

Following were the outcomes variable of our purposed study design

### Independent Variable:

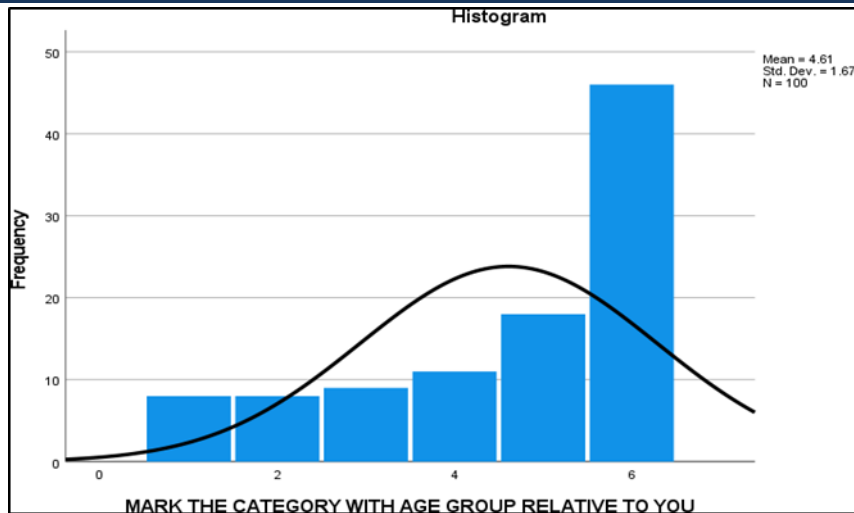
- Geographical barriers
- Life style
- Comorbidities
- Dietary habits
- Marital status

### Dependent Variable:

- Age
- Gender
- Breast Density
- Presence and characteristics of breast lesions.

## RESULT AND DISCUSSION

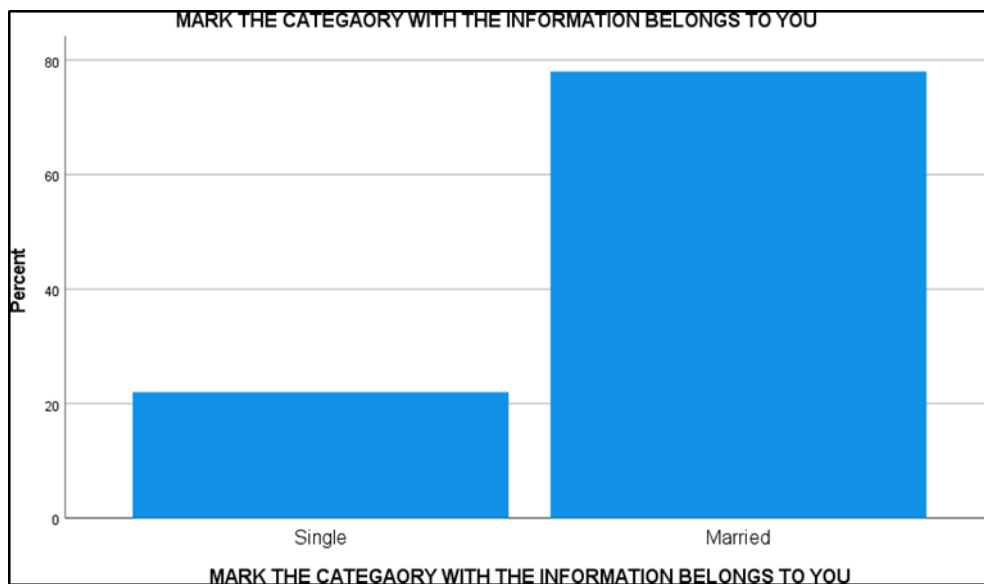
It presents findings of the study, analyzing the ability of ultrasound imaging with BI-RADS classification to accurately diagnose the breast lesions in women, considering the potential confounding factors such as breast density and tissue inflammation. Understanding demographic distribution of the study participants is crucial for contextualizing findings. This study included women across various age groups and marital statuses.



**Figure 1:** The Age Distribution of Participants

A total of 100 women participated in this study. Age distribution showed a higher prevalence of participants above 35 years (46%). Other age groups included 8% under 15 years, 8% between 15-19 years, 9% between 20-24 years, 11% between 25-29 years, and the 18% between 30-34 years. The most dominant age group was 35 – 45

(most commonly the age of pre – menopausal and menopause females. At this age female are likely to have tissue inflammation (infectious as well noninfectious). The purpose of taking most samples from above mentioned age group was to have more cases with confounding factors.

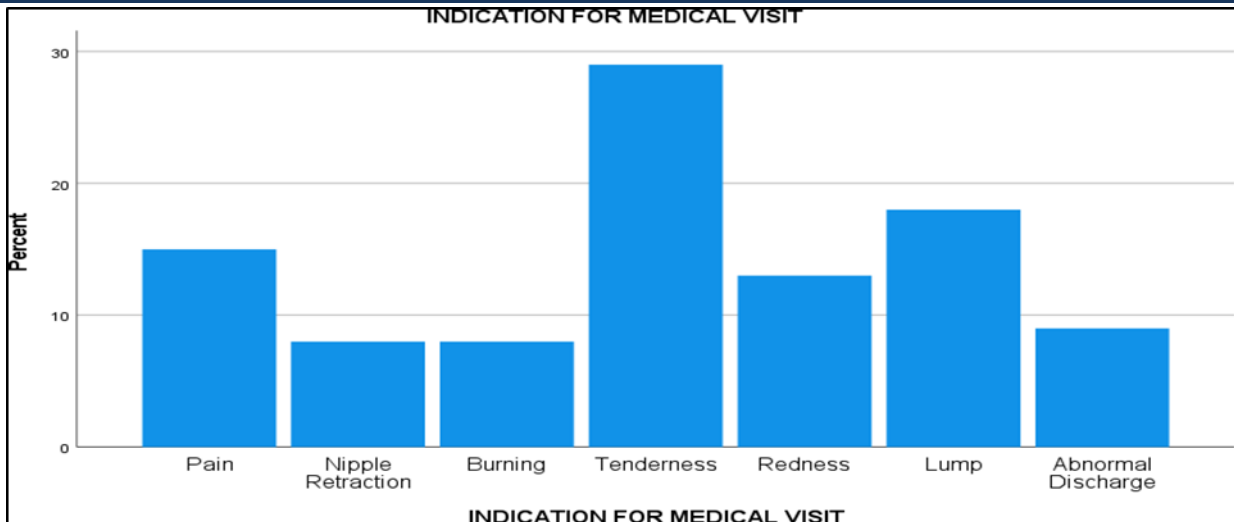


**Figure 2:** The Marital Status of Participants

The majority of participants were married (78%) and 22% were single. Among 78 % of females, the chances of nursing mothers were high. Feeding mothers are prone to necrotic or traumatic tissue

inflammation, (most commonly by hit from baby's head). According to our proposed hypothesis we find 50 % cases with tissue inflammation.



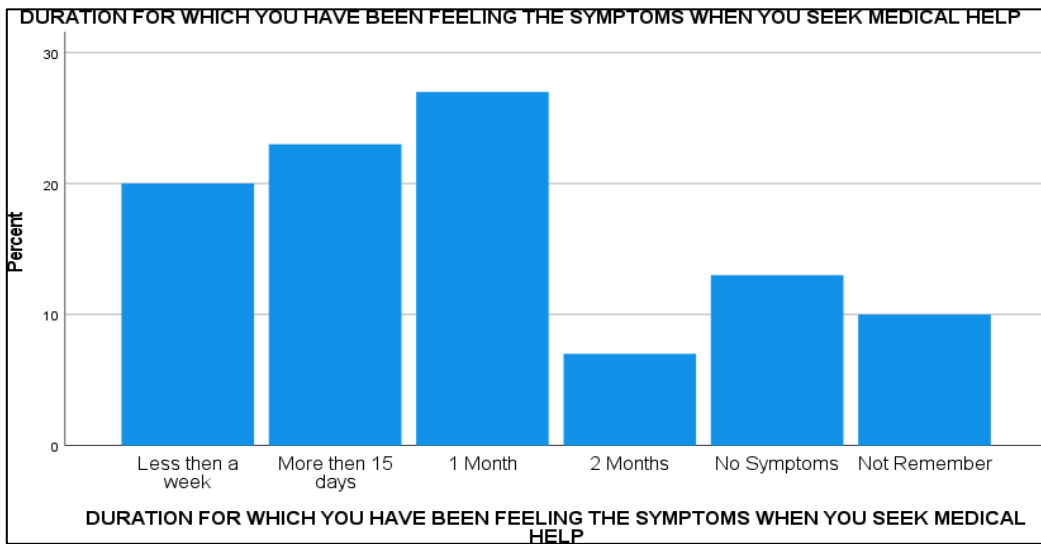


**Figure 3:** The indications for medical visit

Identifying the reasons for seeking medical attention helps in understanding the symptomatic presentation of breast lesions in patients. These indications reflect the common symptoms that prompt women to undergo breast ultrasound imaging, providing a basis for understanding the clinical context in which the BI-RADS classification system is applied.

Patients with symptoms of pain, tenderness or redness may be an indication of tissue inflammation.

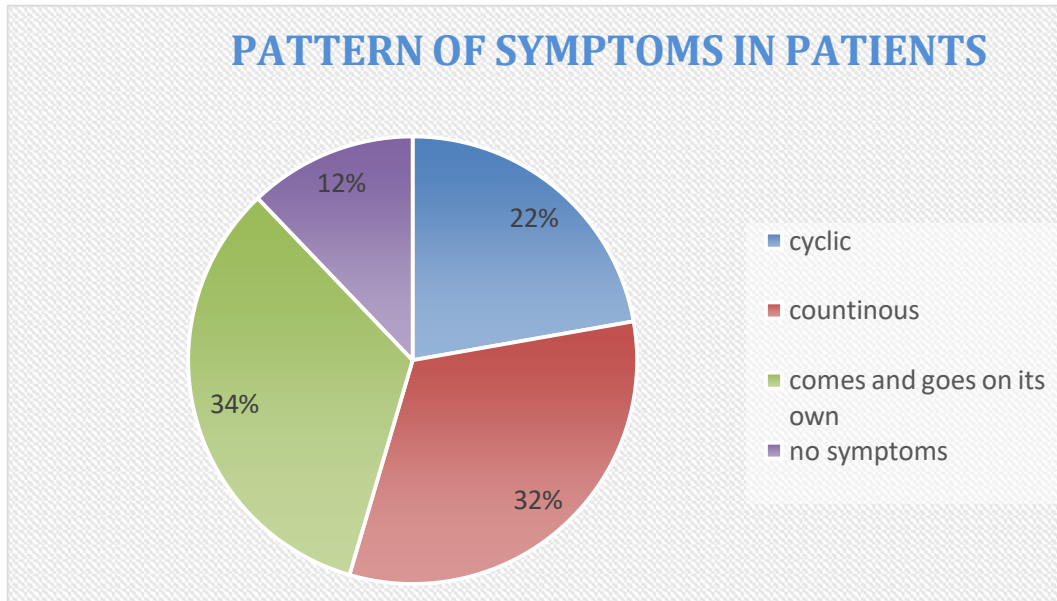
The percentage of various symptoms was as follows Pain (15%) and tenderness (29%) were the most common reasons for seeking medical help by participants, followed by the presence of a lump (18%), redness (13%), abnormal discharge (9%), nipple retraction (8%), and burning sensation (8%). Accumulatively the three most common symptoms of inflammation accounts for almost 50 %.



**Figure 4:** Symptoms Duration in Participants

The duration and pattern of symptoms provide insights into the progression and variability of breast conditions. Symptoms varied in their duration and pattern. These variations in symptom duration and pattern of patients highlight need for tailored diagnostic approaches and the importance of timely medical consultation. Symptoms

duration varied among patients, with 20% experiencing symptoms for less than a week, 23% for more than 15 days, 27% for one month, and 7% for two months. 13% had no symptoms when they sought medical help. The symptom patterns included continuous (32%), cyclic (23%), intermittent (33%), and no symptoms (12%).

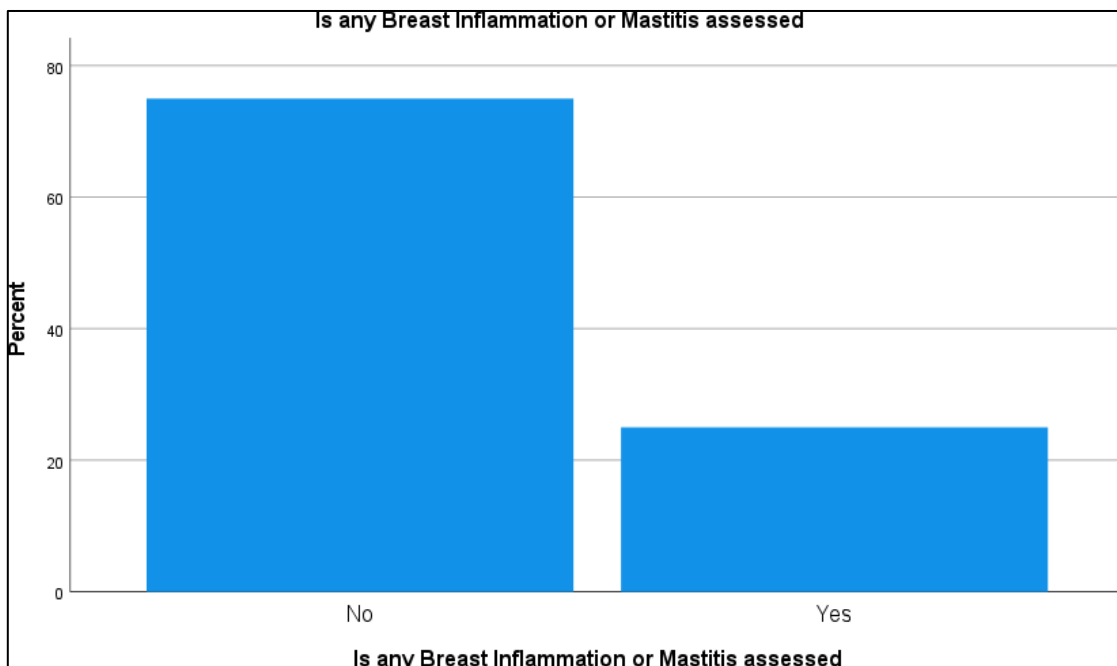


**Figure 5:** pattern of Symptoms in Participants

Patterns of symptoms were different in patients. 32 % patients were with continuous symptoms indicating that there has been an underlying pathology that is continuously showing symptoms. However, our area of interest was patients with cyclic and with the symptoms that comes and disappears on its own with irregular pattern. 22 % patients exhibit cyclic and 34 % shows irregular pattern. Accumulatively these two patterns account

for almost 50 %.

The above mentioned pattern of symptoms may be an indication of hormonal imbalance (pre-menopausal and post-menopausal) or the acute pathology to which immune system has been trying to coping with. The pattern of symptoms strongly in favor of tissue inflamed, highly dense breasts with mastalgia etc.



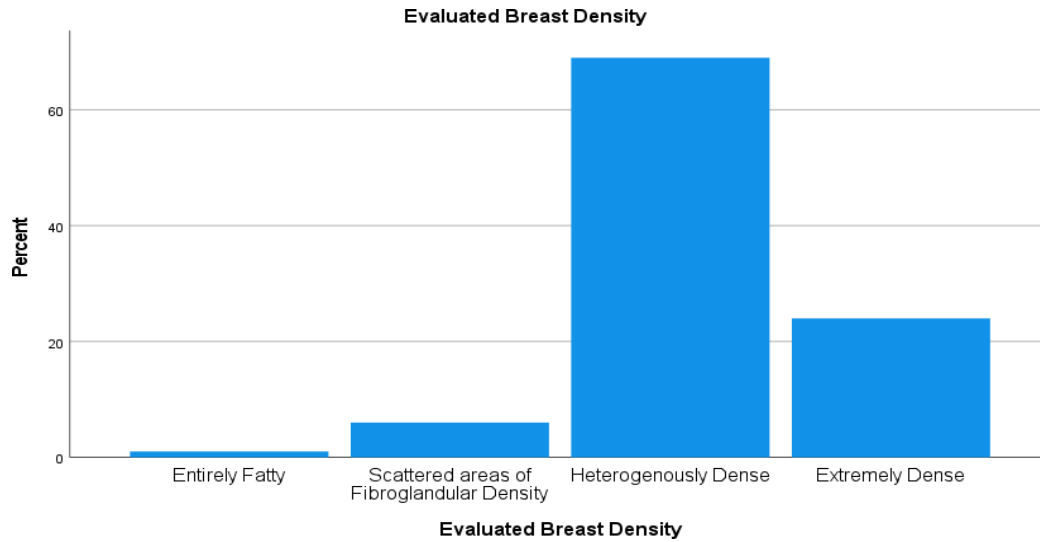
**Figure 6:** presence of inflammation

Inflammation and surrounding tissue changes are critical factors that can influence the accuracy of

ultrasound imaging. Mastitis or tissue inflammation can alter tissue characteristics, can

complicate the diagnostic process and affect the accuracy of BI-RADS classification. This question clearly addresses the presence or absence of inflamed tissues. The answer was given by medial reports of patients. Category wise division was as metioned below depending on the feature

displayed on ultrasound. Breast inflammation or mastitis was present in 25% of participants, with mild (4%), moderate (14%), and severe (7%) cases. Changes in surrounding tissues in breast were abnormal in 26% of cases. The findings related to mass or lump were present in 55%.



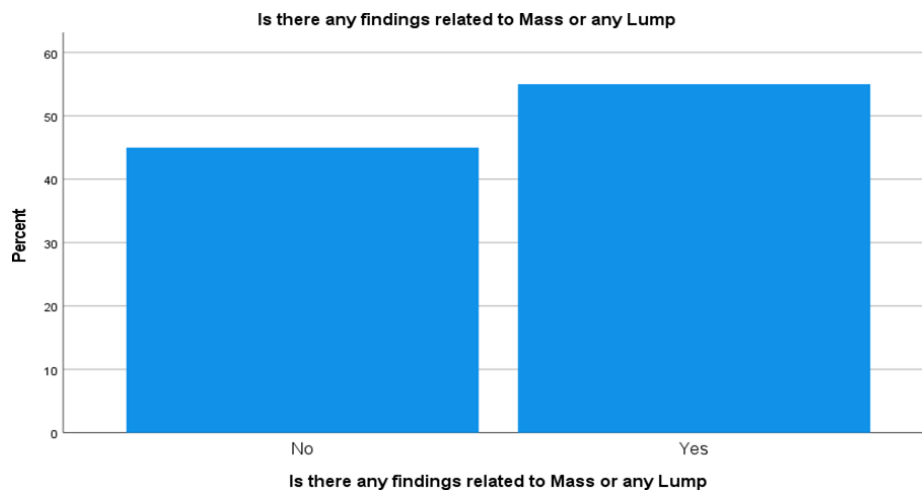
**Figure 7:** breast composition, echo pattern and density

**Breast Composition, Echo Patterns, and Density**

Another factor we find on ultrasound was echo pattern. Evaluating the breast composition and echo patterns is essential for understanding the imaging characteristics of breast tissue. These findings suggest a diverse range of breast tissue types and echo characteristics in participants, which can influence interpretation of ultrasound images and the application of BI-RADS categories. Highly dense breast shows echo pattern that may mimics or hide pathology.

**Despite Presence of Echo Pattern Variations Our Goal Was to Rule Out Underlying Pathology.**

The percentage was as follows, Breast composition was heterogeneous in 55% of total cases, homogenous fibro glandular in 24%, and homogenous fatty in 21%. The echo patterns were hyperechoic in 43%, hypoechoic in 33%, isoechoic in 17%, and complex in 7%. Breast density was heterogeneously dense in the 69% of participants, extremely dense in 24%, scattered fibro glandular in 6%, and entirely fatty in 1%.



**Figure 8:** Mass or Lump Presence in Participants

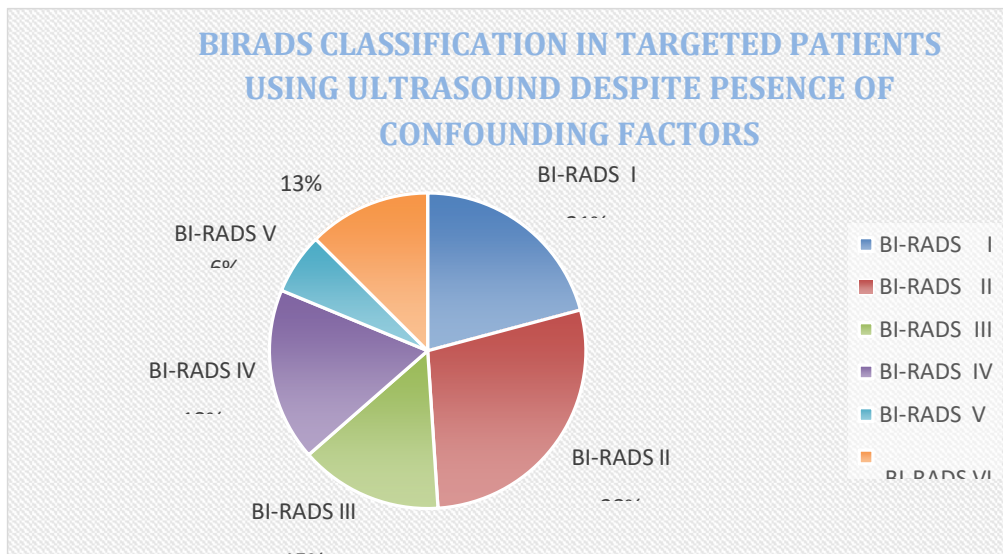
Identifying the presence of masses is vital for

assessing the severity and nature of breast lesions.

These findings highlight variability in breast lesion presentations and importance of comprehensive ultrasound evaluation to accurately categorize and diagnose breast conditions. The BI-RADS classification system is a standardized method used to categorize the breast imaging findings. The distribution of BI-RADS categories provides insights into diagnostic outcomes and the accuracy of BI-RADS in classifying a wide range of breast lesions, including benign and malignant cases.

Almost 80 % patients were with mass or lump or lesion in addition to presence of confounding factors. The Mass shape in breast was irregular in

25% of cases, round or oval in 22%, and absent in 45%. The mass orientation was unparallelled in 24%, and parallel in 18%. Mass margins were ill-defined in 20%, defined and sharp in 19%, and absent in 45% patients. The mass vascularity was increased in 20% of cases. Posterior acoustic features of mass or lump included enhancement (15%) and shadowing (28%). These results suggest that ultrasonic diagnosis was effective in determining the features of breast lesion with zero effect o its accuracy because of presence of inflamed and dense breast tissues.



**Figure 9:** BIRADS Classification Diversity in Participants

Final results of imaging 100 cases under USG guidance was highly in favor of USG usage in patients with confounding factors. BI-RADS classification in participants showed 27% in category 2, 20% in category 1, 17% in category 4, 14% in category 3, 12% in category 6, 6% in category 5, and 4% in category 0. The pathology diagnosed was unilateral in 80% and bilateral in 20%.

These values suggest that ultrasound imaging has clearly assigned one of BI-RADS class to all of the cases understudy. This points and concludes that Ultrasound imaging is sufficient and effective in diagnosis and classification of pathology despite presence of confounding factors.

**DISCUSSION**

The data indicates that ultrasound imaging with BI-RADS classification is an effective method for categorizing the breast lesions. This conclusion is significant given inherent complexity and

variability of breast tissue characteristics among women. Factors such as tissue inflammation and breast density have the potential to confound the diagnostic process, but the results from this study suggest that BI-RADS classification remains a robust tool in most scenarios.

Breast density is a critical factor in the breast imaging. High breast density can obscure lesions and reduce sensitivity of mammography. However, in this case ultrasound imaging, which is less affected by breast density, provides a valuable complementary method. The study revealed that a majority of the participants in this study had heterogeneously dense breasts (69%), yet the BI-RADS classification was still able to categorize lesions effectively. This finding underscores the adaptability and reliability of ultrasound imaging in dense breast tissues, where mammography alone might be insufficient.

Tissue inflammation of breast, or mastitis, presents



another diagnostic challenge as it can mimic or obscure presence of lesions. In this study, 25% of participants had inflammation or mastitis, with varying degrees of severity. Despite this, the BI-RADS classification system provided consistent categorization of lesions. This suggests that BI-RADS criteria are sufficiently detailed to account for inflammatory changes in the breast tissue, though the presence of inflammation requires careful consideration by radiologist to avoid misinterpretation.

The distribution of BI-RADS categories in this study (27% in category 2, 20% in category 1, 17% in category 4, etc.) illustrates range of the diagnostic outcomes and highlights nuanced nature of the breast lesion classification. Categories such as BI-RADS 4 and 5, which indicate a higher suspicion of malignancy in patients, were effectively identified, ensuring that patients with potentially serious conditions received appropriate follow-up and intervention.

Despite these positive findings of study, it also highlights areas for further research. The sensitivity and specificity of the BI-RADS classification system in presence of high breast density and inflammation need more detailed investigation. Future studies should aim to quantify how these confounding factors impact the diagnostic accuracy and explore whether modifications to the BI-RADS criteria could enhance its precision.

Additionally, the study emphasizes significance of a multidisciplinary approach in breast cancer diagnosis. Combining ultrasound with other imaging modalities, such as mammography and MRI, could improve diagnostic efficiency, especially in complex cases involving dense breast tissue or significant inflammation. Radiologists should be trained to recognize the limitations of each modality and use them complementarily to provide best possible patient outcomes.

In conclusion, while ultrasound imaging with BI-RADS classification proves to be an accurate diagnostic tool for breast lesions, careful consideration of confounding factors like breast density and inflammation is crucial. The study supports robustness of the BI-RADS classification system but also calls for ongoing refinement and validation to maintain its reliability across the diverse patient populations. The integration of multiple imaging modalities and continued research will be essential to advancing the breast cancer diagnostics and improving patient care.

## SUMMARY, KEY FINDINGS, CONCLUSIONS, AND RECOMMENDATIONS

### Overview

The very first detection of diseases of breast is key element for patient survival. Imaging modalities but due to some socio cultural barriers females' faces lack of health facilities. This is the reason that breast cancer is causing highest mortality after lung cancer in females. Among imaging modalities in Pakistan ultrasound is easily available and accessible. This research has covered the efficiency of ultrasound in diagnosing breast diseases in spite of confounding factors such as tissue inflammation and breast density (most of female's patients has either of above two conditions).

In this study 100 females have participated. 50 % of them were with tissue inflammation and almost 25 % of them were young with highly dense breasts.

Comparing pathological and radiological findings and IBM SPSS software results analysis ultrasound imaging was effective in accurate diagnosis and classification of pathology according to BI RaDS.

### Key Findings

50 % of females participated in this study were medically diagnosed with tissue inflammation, with 25% of them were with mastitis (infectious inflammation of breasts in post-menopausal phase) and 20 % were with any traumatic / fibrocystic inflammation (most of them were nursing mothers). 25 % were with highly dense breast.

4% of females were placed in BI RADS category 0. 20 % were of BIRADS category I, 27% were in NBIRaDS II, 14 % with BI RaDS IV, 17 % with BI RaDS IV, 6% with BI RaDS V and 12% with BI RaDS VI.

These findings were strongly indicating in favor of ultrasound in patients with confounding factors.

### CONCLUSION

Breast imaging using Ultrasound is highly reliable in patients with confounding factors that may hinder or influence the underlying pathology such as tissue inflammation and breast density. It can be used as and 1<sup>st</sup> line modality before mammography in dense breasts and MRI in elderly inflamed breasts. This research shows ultrasound has accurately classified targeted 100 cases of breasts diseases according to BI RADS classification.

## LIMITATIONS

This research has been carried out in radiology departments of government hospitals of Faisalabad where patient burden was high. Complete medical history with informed consent form was collected. However, certain limitations fall out in the proposed method.

- Difficulty to obtain complete medical history of patients because of poor management of data in hospitals.
- Hesitation of patients with no or minimal symptoms for visit to hospital.
- Eye to eye Variation of results due to experience of sonographers

## RECOMMENDATIONS

Despite the overburden of patients visiting the hospitals, there should be a proper system of data management utilizing new modes of technology so that flaws in data collection can be minimized. Proper awareness to remote and developing areas of Pakistan should be provided so that females can understand the importance of self and screening as well as early diagnosis.

Overcoming these limitations can prove to be a blessing for researchers and medical health care persons as the proper availability of data is necessary for patient safety as well as for a better treatment plan. For researchers, it can be a milestone as many aspects of disease prognosis, spread, and resistance can be unvalued.

## FUTURE RECOMMENDATIONS

As ultrasound is easily accessible and non-invasive, non-ionizing, low cost imaging modality. It is available in developing countries like Pakistan where deadly breast cancer is devastating lives; it would be a milestone if ultrasound can be used in patients with confounding factors. It might be better for patients who cannot undergo imaging via MRI due to unavailability in remote areas and contraindicated patients for early diagnosis.

Since the last 50 years, ultrasound has been getting advancement day by day. The future of ultrasound imaging in breast seems to be replacing MRI. Here is the brief introduction of some advancement.

New developments in ultrasound technology have been made and are being further enhanced for the detection and diagnosis of breast cancer. New technologies were designed to enhance diagnostic accuracy: computer-aided detection, elastography,

quantitative breast ultrasound technologies, and ultrasound contrast agents (microbubbles). These measures may positively affect the overall survival of patients by detecting small, less aggressive cancers.

### Contrast-enhanced ultrasound of the breast is more sensitive

Novel studies have shown improved visibility and intensity for Doppler signals thanks to the use of ultrasound contrast agents (microbubbles).

### Computer Aid- Detection

CAD for ultrasound may be considered as a twin of CAD for mammography, aimed at enhancing the final diagnostic performance provided by the interpreting radiologist.

### Elastography

Elastography indicates the divergence between the normal tissue and the adjacent tumors, enhancing specificity and diagnostic consideration; this technology is now installed on all ultrasound machines. The two most widely employed elastography techniques for breast purposes are strain elastography and shear-wave elastography. Reports suggest shear-wave technology is highly reproducible, as opposed to strain elastography, which may present with considerable inter-observer variability.

### Quantitative breast ultrasound

Quantitative breast ultrasound quantifies the sound transmission and speed through the breast. Imaging is performed with a ring transducer that sends the ultrasound through the breast.

## REFERENCES

1. World Health Organization. "Breast Cancer." 13 March 2024.
2. Khan, P., Masroor, I., Alam, M. S., Salam, A., Ali, Y., & Khan, M. S. "Sonographic Characteristics and Pathology Correlation of Breast Imaging Reporting and Data System (BI-RADS) Category 4 Lesions." *Cureus* 15.12 (2023).
3. Rapelyea, J. A., & Marks, C. G. "Breast Imaging: Breast Ultrasound Past, Present, and Future." In Kuzmiak, C. M. (Ed.), *Intech Open* (2017).
4. Asif, H. M., Sultana, S., Akhtar, N., Rehman, J. U., & Rehman, R. U. "Prevalence, Risk Factors, and Disease Knowledge of Breast Cancer in Pakistan." *Asian Pacific Journal of Cancer Prevention* 15.11 (2014): 4411-4416.

5. Sanders, R. C., & Hill, B. "Clinical Sonography." *Lippincott Williams & Wilkins* (2006).
6. Carr-Hoefler, C. "Granular Cell Tumor: A Benign Mimicker of Breast Carcinoma." *Journal of Diagnostic Medical Sonography* 19.2 (2003): 95-100.
7. Malik, N., Rauf, M., & Malik, G. "Diagnostic Accuracy of Ultrasound BI-RADS Classification Among Females Having Breast Lumps, by Taking Histopathology as Gold Standard." *Journal of The Society of Obstetricians and Gynaecologists of Pakistan* 10.1 (2020): 13-16.
8. Kim, J. Y., Jung, E. J., Park, T., Jeong, S. H., Jeong, C. Y., Ju, Y. T., ... & Choi, S. K. "Prognostic Importance of Ultrasound BI-RADS Classification in Breast Cancer Patients." *Japanese Journal of Clinical Oncology* 45.5 (2015): 411-415.
9. Kim, E. K., Ko, K. H., Oh, K. K., Kwak, J. Y., You, J. K., Kim, M. J., & Park, B. W. "Clinical Application of the BI-RADS Final Assessment to Breast Sonography in Conjunction with Mammography." *American Journal of Roentgenology* 190.5 (2008): 1209-1215.
10. Lee, H. J., Kim, E. K., Kim, M. J., Youk, J. H., Lee, J. Y., Kang, D. R., & Oh, K. K. "Observer Variability of Breast Imaging Reporting and Data System (BI-RADS) for Breast Ultrasound." *European Journal of Radiology* 65.2 (2008): 293-298.
11. Lazarus, E., Mainiero, M. B., Schepps, B., Koelliker, S. L., & Livingston, L. S. "BI-RADS Lexicon for US and Mammography: Interobserver Variability and Positive Predictive Value." *Radiology* 239.2 (2006): 385-391.
12. Bray, F., Laversanne, M., Sung, H., Ferlay, J., Siegel, R. L., Soerjomataram, I., & Jemal, A. "Global Cancer Statistics 2022: GLOBOCAN Estimates of Incidence and Mortality Worldwide for 36 Cancers in 185 Countries." *CA: A Cancer Journal for Clinicians* 74.3 (2024): 229-263.
13. Sehgal, C. M., Weinstein, S. P., Arger, P. H., & Conant, E. F. "A Review of Breast Ultrasound." *Journal of Mammary Gland Biology and Neoplasia* 11 (2006): 113-123.
14. Sickles, E. A. "ACR BI-RADS® Atlas, Breast Imaging Reporting and Data System." *American College of Radiology* (2013): 39.
15. Gokhale, S. "Ultrasound Characterization of Breast Masses." *Indian Journal of Radiology and Imaging* 19.3 (2009): 242-247.
16. Fisher, M. P. R. "Breast Cancer Ultrasonography: Practice Essentials, Role of Ultrasonography in Screening, Breast Imaging Reporting and Data System." (2021).
17. Bodewes, F. T. H., Van Asselt, A. A., Dorrius, M. D., Greuter, M. J. W., & De Bock, G. H. "Mammographic Breast Density and the Risk of Breast Cancer: A Systematic Review and Meta-Analysis." *The Breast* 66 (2022): 62-68.
18. Yuan, W. H., Hsu, H. C., Chen, Y. Y., & Wu, C. H. "Supplemental Breast Cancer-Screening Ultrasonography in Women with Dense Breasts: A Systematic Review and Meta-Analysis." *British Journal of Cancer* 123.4 (2020): 673-688.
19. O'Flynn, E. A., Fromageau, J., Ledger, A. E., Messa, A., D'Aquino, A., Schoemaker, M. J., ... & Bamber, J. C. "Ultrasound Tomography Evaluation of Breast Density: A Comparison with Noncontrast Magnetic Resonance Imaging." *Investigative Radiology* 52.6 (2017): 343-348.
20. Jung, S. L., Baek, J. H., Lee, J. H., Shong, Y. K., Sung, J. Y., Kim, K. S., ... & Kulkarni, S. "Imaging Features of Inflammatory Breast Disorders: A Pictorial Essay." *Korean Journal of Radiology* 19.1 (2018): 5-14.
21. Sood, R., Rositch, A. F., Shakoor, D., Ambinder, E., Pool, K. L., Pollack, E., & Harvey, S. C. "Ultrasound for Breast Cancer Detection Globally: A Systematic Review and Meta-Analysis." *Journal of Global Oncology* (2019).
22. Febery, A., & Bennett, I. "Sonographic Features of Inflammatory Conditions of the Breast." *Australasian Journal of Ultrasound in Medicine* 22.3 (2019): 165-173.
23. Rosenberg, R. D. "Accuracy of Classification of Breast Ultrasound Findings Based on Criteria Used for BI-RADS." *Breast Diseases: A Year Book Quarterly* 2.20 (2009): 150.
24. Ghaemian, N., Tehrani, N. H. G., & Nabahati, M. "Accuracy of Mammography and Ultrasonography and Their BI-RADS in Detection of Breast Malignancy." *Caspian Journal of Internal Medicine* 12.4 (2021): 573.
25. Chang, J. M., Won, J. K., Lee, K. B., Park, I. A., Yi, A., & Moon, W. K. "Comparison of Shear-Wave and Strain Ultrasound Elastography in the Differentiation of Benign and Malignant Breast Lesions." *American*

- 
- Journal of Roentgenology* 201.2 (2013): W347-W356.
26. Berg, W. A., Cosgrove, D. O., Doré, C. J., Schäfer, F. K., Svensson, W. E., Hooley, R. J., ... & BE1 Investigators. "Shear-Wave Elastography Improves the Specificity of Breast US: The BE1 Multinational Study of 939 Masses." *Radiology* 262.2 (2012): 435-449.
27. Duric, N., Li, C., Littrup, P., Glide-Hurst, C., Huang, L., Lupinacci, J., ... & Xu, Y. "Multi-Modal Breast Imaging with Ultrasound Tomography." *Medical Imaging 2008: Ultrasonic Imaging and Signal Processing*. Vol. 6920. *SPIE*, 2008.

**Cite this article as:**

Ali, S., Abdullah, M., Fatma, M., Fatima, N., Salam, A., Jamro, A. and Hayat, L. "Ultrasound Imaging with Birads Classification: A Reliable Diagnostic Tool for Breast Lesions in Women with Confounding Factors." *Sarcouncil journal of Medical sciences* 4.3 (2025): pp 1-16.